

Intraoperative neurophysiological monitoring to protect the facial nerve during microsurgery for large vestibular schwannomas

Xipeng XU^{1*}, Huaxin LIANG^{1*}, Xiao ZHANG², Long MA¹, Conghai ZHAO¹, Libo SUN¹

¹ The Department of Neurosurgery, China-Japan Union Hospital of Jilin University, No.126 Xiantai Street, Changchun, China;

² The Neural Electrophysiology Center, China-Japan Union Hospital of Jilin University, No.126 Xiantai Street, Changchun, China

* Authors contributed equally to this work

Correspondence to: Libo Sun MD., PhD.
Department of Neurosurgery, China-Japan Union Hospital, Jilin University
ChangChun, 130033, Jilin Province, China.
TEL: +86-13104318588; E-MAIL: sunlibo@jlu.edu.cn

Submitted: 2016-07-16 Accepted: 2016-11-12 Published online: 2017-05-15

Key words: **large vestibular schwannomas; microneurosurgery; intraoperative neurophysiological monitoring; facial nerve**

Neuroendocrinol Lett 2017; **38**(2):91-97 PMID: 28650602 NEL380217A01 © 2017 Neuroendocrinology Letters • www.nel.edu

Abstract

OBJECTIVE: Microsurgery is the preferred treatment for large vestibular schwannomas (VSs). However, anatomical and functional preservation of the facial nerve (FN) remains a challenge during this surgery. The aim of this study was to determine whether it is beneficial to the preservation rates of the FN during microsurgical treatment of large VSs using intraoperative neurophysiological monitoring (IONM).

METHODS: We retrospectively reviewed 53 patients with large VSs that underwent microsurgical resection via the retrosigmoid approach in our department during April 2009 to March 2016. IONM was used in 29 cases. Postoperative FN function was evaluated using the House-Brankmann (HB) FN grading scale at 2 weeks and 3 and 6 months after surgery.

RESULTS: There were two cases (8.3%) of subtotal resection in the monitored group, compared with one case (3.4%) among the controls ($p>0.05$). The anatomical integrity rate for FNs was 100% in the monitored group, which was significantly different from 83.3% in the controls ($p<0.05$), which included four cases the FN was injured, mostly around the internal auditory foramen. Functional preservation of the FN in the monitored group differed significantly from that in the controls at 2 weeks and 3 and 6 months postoperatively ($p<0.05$).

CONCLUSIONS: IONM contributes to FN anatomical integrity and functional preservation rates during microsurgery of large VSs. It has no significant effect on differences in the total VS resection rates.

INTRODUCTION

Vestibular schwannomas (VSs) typically arise from abnormal proliferation of Schwann cells on the vestibular nerve in the internal auditory canal (IAC). They comprise 8% of cranial tumor cells and 90% of the cells in cerebellopontine angle tumors (Koos *et al.* 2002). VSs can be classified as small (<15 mm), medium (15–30 mm), or large (≥ 30 mm) according to the maximum extrameatal diameter measured using axial computed tomography (CT) or magnetic resonance imaging (MRI). Microsurgical treatment is recommended for large VSs (Myrseth *et al.* 2007; Quesnel *et al.* 2011; Samii *et al.* 2010). With the increasing use of microsurgery, the death rate associated with VS resection has declined to <1% (Moskowitz *et al.* 1991). The rate of functional preservation for the facial nerve (FN), however, is still <75% (Ojemann *et al.* 2001) because it is being stretched, compressed, or invaded by VS, which is not obvious to the naked eye. As a result, protecting the FN during microsurgical treatment of large VSs is still a challenge.

METHODS AND MATERIALS

Patients

Retrospectively, we identified 53 patients with VS who had undergone microsurgical resection via the retrosigmoid approach at the Neurosurgery Department of

China-Japan Union Hospital of Jilin University from April 2009 to March 2016. Among them, 29 of the patients were subjected to intraoperative neurophysiological monitoring (IONM). Patients who had no complications of cardiac, respiratory, or other cranial diseases were included. Patients who had other diseases that could cause FN injury were excluded.

The VSs were measured according to the maximum extrameatal diameter obtained using axial MRI or CT. Preoperative FN functions were evaluated using the House-Brankmann FN grading scale (HB grade) (House *et al.* 1985). The baseline data for the two groups are shown in Table 1. There were no significant differences between the two groups according to data analysis.

Monitoring techniques

FN monitoring was performed with the XLTEK Pro-tekto 32 IOM system (Natus Medical, Pleasanton, CA, USA). The FN monitoring protocols can be divided primarily into two types.

Electromyography (EMG): Intramuscular needle electrodes were inserted into the muscles innervated by the FN of the affected side (orbicularis oculi, orbicularis oris, and mentalis muscles). In addition, a bipolar electrical stimulation probe was used during the surgical procedure with a current of <1 mA (mostly 0.1–0.5 mA).

Motor evoked potentials for FN monitoring, also known as facial motor evoked potentials (FMEPs) (Moskowitz *et al.* 1991): FMEPs were obtained from electrodes inserted into the stylomastoid foramen, through which the FN traveled. The transcranial electrical stimulation was performed using corkscrew-like electrodes inserted into the scalp and positioned at CZ and at C3 or C4 for left-side or right-side stimulation, respectively. Stimulation was applied contralateral to the affected side using one, three, or five rectangular pulses of 200–600 V, with 50 s of pulse duration and an inter-stimulus interval of 2 ms. The number of pulses and stimulus intensity were increased according to facial and hand MEP responses. A train-of-five pulse was used only in cases of an unsatisfactory response to a train-of-three pulse.

Anesthesia techniques

All of the patients were placed under general anesthesia, which was induced with fentanyl ($3 \mu\text{g}\cdot\text{kg}^{-1}$), propofol ($2 \text{mg}\cdot\text{kg}^{-1}$), and cisatracurium ($0.15 \text{mg}\cdot\text{kg}^{-1}$). Anesthesia was maintained with fentanyl ($0.4 \mu\text{g}\cdot\text{kg}^{-1}\cdot\text{min}^{-1}$) and propofol ($5 \text{mg}\cdot\text{kg}^{-1}\cdot\text{h}^{-1}$). Cisatracurium was discontinued, and the minimal alveolar concentration (MAC) of sevoflurane was limited to <0.5.

Surgical procedures

All tumors were resected via the retrosigmoid approach in both the controls and the 29 patients with IONM. The patients were positioned in a lateral decubitus pos-

Tab. 1. The baseline data in two groups [n(%), $\bar{x}\pm 5$].

	Monitored group	Control group
Case number	29	24
Gender ^a	Male	13(44.8)
	Female	16(55.2)
Age(year) ^b	48.38 \pm 9.01	50.58 \pm 8.91
Characters of VS ^{a,b}	Diameter (mm)	40.34 \pm 7.19
	Solid	20(69.0)
	Cystic	9(31.0)
HB grade of FN ^c	Grade I	22(75.9)
	Grade II	4(13.8)
	Grade III	3(10.3)
	Grade IV	0
	Grade V	0
	Grade VI	0

^a χ^2 test: There are no significant differences in male/female ratio ($p=0.817>0.05$) and solid/cystic ratio ($p=0.096>0.05$) between two groups.

^b t test: There are no significant differences in ages ($p=0.377>0.05$) and diameters of VS ($p=0.620>0.05$) between two groups.

^c rank-sum test: There is no significant difference in HB grade ($p=0.705>0.05$) between two groups.

ture. Retromastoid craniotomy was performed. The dura was opened under the microscope in semilunar fashion parallel to the course of the sigmoid sinus. After sufficient release of cerebrospinal fluid from the cistern magna, the posterior surface of the tumor was exposed. The capsule was then opened and debulked with an ultrasonic surgical aspirator until the tumor's mass was significantly reduced. The IAC was drilled in a lateral to medial direction, the intrameatal part of the VS was removed, and the FN was identified. The FN was carefully protected when being separated from the VS's capsule. Subtotal removal was performed when the tumor was tightly adherent to the facial nerve or brain stem to preserve function and avoid complications. Careful hemostasis was performed, and the drilled area of the IAC was sealed. The dura was sutured in a watertight fashion, the bone flap was replaced and fixed, and the incision was closed.

Follow-up of FN function

Postoperative FN function at 2 weeks and 3 and 6 months after surgery were evaluated according to the HB grade (House *et al.* 1985). Grades I and II were considered to indicate good function, and grades III and VI poor function.

Data analysis

All data were analyzed using SPSS 18.0 (SPSS, Chicago, IL, USA). Measurement data were expressed as the mean \pm SD. Statistical significance was evaluated using the t-test. Numerical data were expressed as a percentage. Statistical significance was evaluated using the χ^2 test for unordered variables, whereas the rank-sum test was used for ordered variables. A value of $p < 0.05$ was considered to indicate significance.

RESULTS

Among the 53 patients with large VSs, the FN was localized in the anterior middle position in 45 cases, anterior upper in 1 case, anterior lower in 5 cases, and interior in 2 cases. The intraoperative FN locations are shown in Table 2.

There were two cases (6.9%) of subtotal resection in the monitored group and one case (4.2%) in the control group. The difference was not significant ($p = 0.672$; based on significance at > 0.05). The VS removal rates are shown in Table 3.

All four cases of incomplete FN removal were in the control group, where the FN was localized around the internal auditory foramen. There was a significant difference between the two groups ($p = 0.024$; < 0.05). The anatomical integrity of the FN is shown in Table 4.

The HB grades were as follows at the three postoperative time points.

Two weeks postoperatively: Control group: HB grade I in 5 cases, HB II in 8, HB III in 4, HB IV in 5, HB V in 2. Monitored group: HB I in 16, HB II in 5, HB

Tab. 2. The intraoperative location of FN[n(%)].

Location	N(%)
Anterosuperior	1(1.9)
Anteromedian	5(9.4)
Anteroinferior	45(84.9)
Interior	2(3.8)
Posterior	0
Sum	53

Tab. 3. The removal ratios of VS[n(%)].

Groups	Total-resection	Subtotal-resection
Control group	23(95.8)	1(4.2)
Monitored group	27(93.1)	2(6.9)
Sum	50	3

Tab. 4. The anatomical integrity of FN[n(%)].

Groups	Complete	Incomplete
Control group	20(83.3)	4(16.7)
Monitored group	29(100)	0
Sum	49	4

III in 4, HB IV in 3, HB V in 1. The differences between the two groups were statistically significant ($p = 0.023$; < 0.05). The HB grades are shown in Table 5.

Three months postoperatively: Control group: HB grade I in 7, HB II in 7, HB III in 5, HB IV in 4, HB V in 1. Monitored group: HB I in 18, HB II in 4, HB III in 4, HB IV in 2, HB V in 1. The differences between the two groups were statistically significant ($p = 0.034$; < 0.05). The HB grades are shown in Table 6.

Six months postoperatively: Control group: HB grade I in 11, HB II in 6, HB III in 3, HB IV in 3, HB V in 1. Monitored group: HB I in 21, HB II in 6, HB III in 1, HB IV in 1. The differences between the two groups were statistically significant ($p = 0.027$; < 0.05). The HB grades are shown in Table 7.

DISCUSSION

Because the FN is adjacent to VSs, it is sometimes compressed so tightly that it is not visible. It is then easily injured during separation because it has become extraordinarily thin or is adherent to the VS. In addition, the exact sites of FNs are uncertain. According to our survey (Table 2), most of the FNs (84.5%) in this study were located anteroinferior to the VS, which made

Tab. 5. HB grade at 2nd week[n(%)].

Groups	I	II	III	IV	V	VI
Control group	5(20.8)	8(33.3)	4(16.7)	5(20.8)	2(8.3)	0
Monitored group	16(55.2)	5(17.2)	4(13.8)	3(10.3)	1(3.4)	0
Sum	21	13	8	8	3	0

Tab. 6. HB grade at 3rd month[n(%)].

Groups	I	II	III	IV	V	VI
Control group	7(29.2)	7(29.2)	5(20.8)	4(16.7)	1(4.2)	0
Monitored group	18(62.1)	4(13.8)	4(13.8)	2(6.9)	1(3.4)	0
Sum	25	11	9	6	2	0

Tab. 7. HB grade at 6th month[n(%)].

Groups	I	II	III	IV	V	VI
Control group	11(45.8)	6(25.0)	3(12.5)	3(12.5)	1(4.2)	0
Monitored group	21(72.4)	6(20.7)	1(3.4)	1(3.4)	0	0
Sum	32	12	4	4	1	0

them invisible because the VS was obstructing any view of them. In one case, the FM was enfolded by the VS, making it vulnerable to injury during tumor resection. As reported by Wiet *et al.* (Wiet *et al.* 2001), the risk of FN dysfunction in the presence of a large VS is sixfold greater than that in patients with small tumors.

The factors causing FN impairment could be divided into three general aspects, according to our experience: (1) mechanical injury: when the FN was compressed, stretched, or even cut; (2) heat injury: when electrocoagulation was used frequently near the FN; (3) ischemic injury: when supply arteries or drainage veins of the FN were damaged. For neurosurgeons, application of IONM offers help in reducing mechanical injury because it gives a real-time warning. As for heat or ischemic injury, the neurosurgeon's experience and skills count more.

There have also been cases in which FN function deteriorated 3 days after the operation for unknown reasons. These cases are defined as delayed facial palsy (Grant *et al.* 2002). Franco-Vidal *et al.* (Franco-Vidal *et al.* 2004) thought this situation was caused by a varicella zoster viral infection. Kuhn *et al.* (Kuhn *et al.* 2012), studying a cell culture model of facial palsy resulting from reactivation of latent herpes simplex type I virus, supported that idea. Our studies found seven patients with symptoms of varicella zoster virus who developed delayed facial palsy, which also supports that idea to some extent.

Other factors that may influence the FN prognosis vary, including the surgical approach. There are three main surgical approaches for VS: middle cranial fossa, retrosigmoid, and translabyrinthine (Ansari *et al.* 2012).

A systematic review (Gurgel *et al.* 2012) of the English-language literature from PubMed published from 1985 to 2011 suggested that there was no significant difference in FN outcomes between the translabyrinthine and retrosigmoid approaches. Hillman *et al.* (Hillman *et al.* 2010) reviewed facial nerve outcomes of patients whose surgery was undertaken via the retrosigmoid or middle fossa approach for the prior 15 years. They concluded that the retrosigmoid approach for VS produces better short-term facial nerve results and a higher percentage of HB grade I results than the middle fossa approach. The retrosigmoid approach was used in all of our patients because it is well known to neurosurgeons and allows panoramic visualization of the cerebellopontine angle and the area posterior to the IAC, which is a versatile route for tumors of any size regardless of pre-operative hearing status (Hillman *et al.* 2010).

The cystic change in VS may also influence the prognosis of the FN. A systematic review (Thakur *et al.* 2012) of English-language literature published between 1990 and 2011 was performed using various search engines including PubMed, Google Scholar, and the Cochrane database. It revealed that FN outcomes are worse in patients undergoing resection of a cystic VS (CVS) than in those undergoing resection of a solid VS (SVS). This conclusion may be based on the fact that the CVS is considered to be more aggressive and less predictable than the SVS. In addition, CVS is notoriously found to be adherent to neurovascular structures (especially the FN), which makes resection difficult. To avoid these biases, we proposed a comparable baseline (Table 1) for each group.

Thus, protecting the FN is still a challenge for neurosurgeons. The application of IONM is considered one of the most useful tools for improving the anatomical integrity and preserving function of the FN (Rahimpour *et al.* 2016). The size of the VS must also be considered, however. The larger the VS, the worse are FN outcomes, regardless of whether IONM is applied. Typically, IONM is accomplished using two techniques (Acioly *et al.* 2013): EMG and FMEP. The electrode recording positions for each of these techniques were described earlier in the article. There are two EMG types, free-run and triggered, each with a different purpose.

Free-run EMG is used to detect facial movements in response to mechanical trauma to the FN during surgical manipulation. Interference with its functioning, however, is a disadvantage. At the beginning of the surgical procedure, it shows a baseline that reflects no mechanical trauma. Later, however, it may experience interference caused by certain electrical items, such as a cellphone or anesthesia machine (Figure 1). Electrocoagulation usage could also interfere (Figure 2) but is easy to identify as all of the electrodes show irregular waveforms. Figure 3 shows a positive waveform but from electrode for cranial nerve (CN) VII (mentalis muscle), which alerts the surgeon to mechanical trauma on parts of the FN (innervating mentalis muscle). In that situation, the neurosurgeon should change the strategy to avoid FN injury.

For triggered EMG, a stimulating probe is used to generate compound muscle action potentials (CMAPs) that are recorded through the electrodes noted earlier. A ground electrode is additionally positioned at the forehead as an adjunct for tracing the FN. Thus, if a tissue is stimulated with a CMAP, it must be a nerve that should be protected. This technique also has some disadvantages, however, as is revealed in Figure 4. If the probe nears electrodes for CN V–VII, for example, at set 3 (12:33:04), CNs V–VII are all stimulated. To avoid this situation, surgeons should stimulate the nerve more precisely. Alternatively, the electrophysiologist could adjust the parameters to identify the nerves. Activation of trigeminal motor fibers typically produces EMG responses within 2–4 ms, whereas facial responses are obtained rather late, at 5–8 ms (Lefaucheur *et al.* 2009).

Aside from localization, the other use for triggered EMG is to predict FN outcomes. Studies (Fenton *et al.* 1999) have shown that immediate FN function was strongly predicted by stimulus intensity, such that the immediate FN function would be HB grade I or II when the stimulus intensity was 0.1–4.0 mA, whereas HB grade IV or worse would indicate an intensity of >10 mA.

Recently, the FMEP technique has been considered a method for predicting FN function. Acioly *et al.* (Acioly *et al.* 2013) indicated that FMEP loss was always related to postoperative facial paresis, although to different degrees. Our data were in accord with theirs. For example, Figure 5 shows that there was no difference in

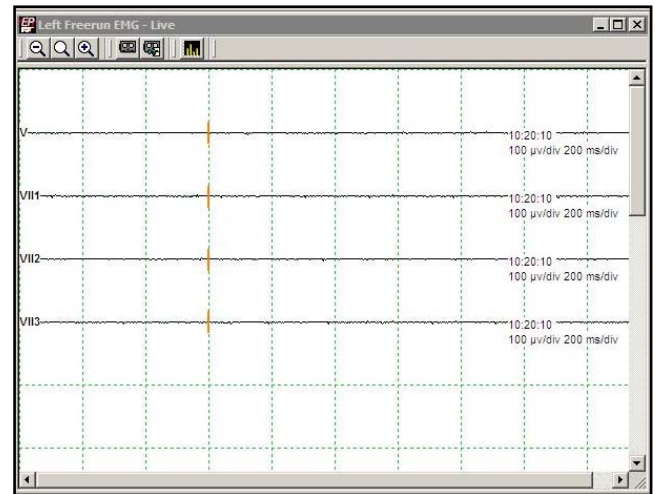


Fig. 1. EMG shows a baseline that reflects no mechanical trauma.

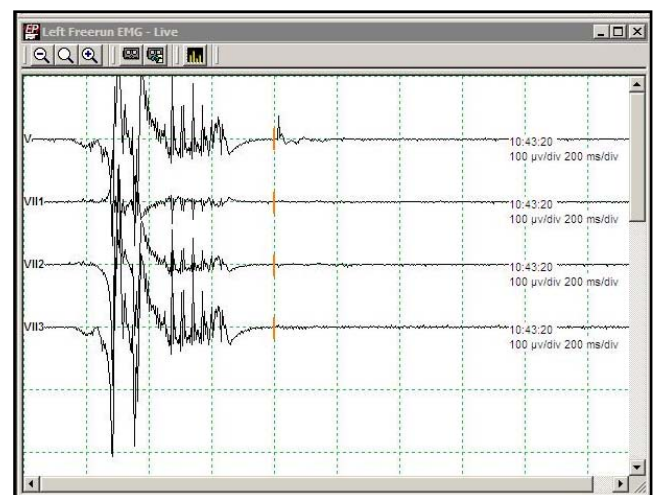


Fig. 2. EMG shows interference by electrocoagulation usage.

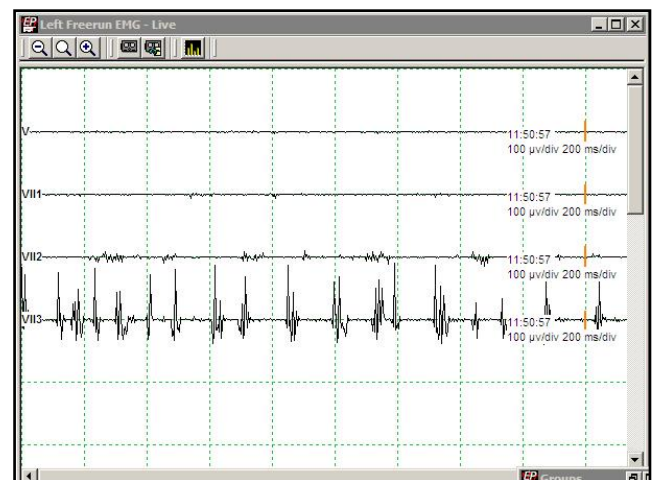


Fig. 3. EMG shows a positive waveform from electrode for CN VII.

FMEPs from 09:53:40 to 14:59:27, so it predicted good FN function (HB grade I or II). Follow-up of FN function confirmed those results.

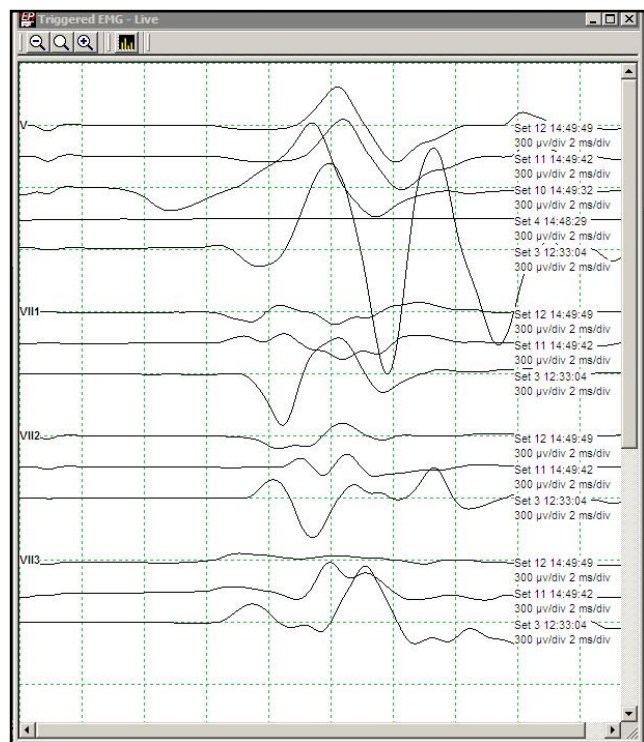


Fig. 4. EMG indicates that the probe is near CN V–VII.

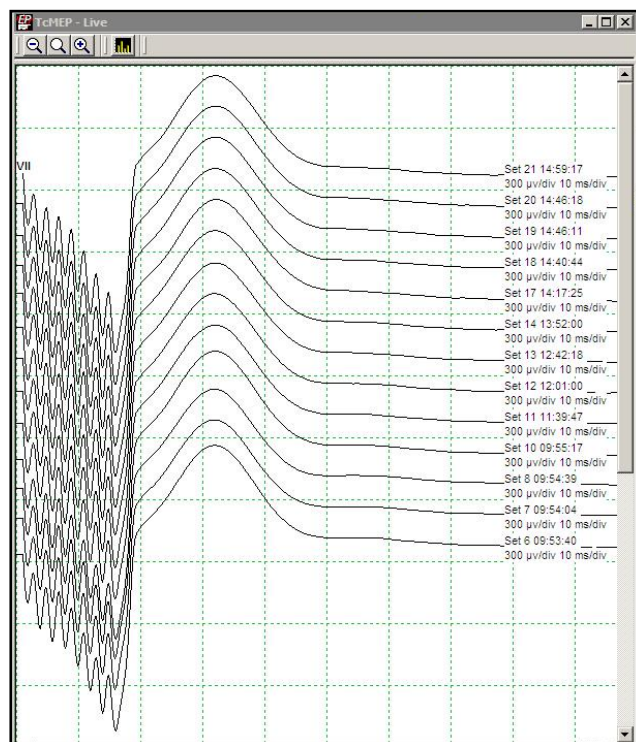


Fig. 5. FMEPs with no differences.

With the help of IONM, neurosurgeons could be more careful during resection of a VS, which could result in more subtotal removal of tumors. Table 3 shows that the monitored group included two cases (6.9%) of subtotal resection, and the control group had one case (4.2%), with no significant difference between the two groups ($p=0.672$; >0.05). These figures indicate that experienced surgical skills also play a crucial role in FN protection.

Postoperatively, there was a significant difference in the anatomical integrity of the FN (Table 4) and in FN function (Table 5–7). Anatomical preservation of the FN was 93.1%, which was in accord with other studies (Youssef *et al.* 2009; Rabelo *et al.* 2011; Oh *et al.* 2012). We therefore concluded that the application of IONM contributes to the anatomical integrity and functional preservation of the FN during the surgical treatment of large VSs. It must be noted, however, that there was no difference in tumor size between two groups.

Anesthesia techniques play a vital role in IONM. The neuromuscular blocking agents were a priority, although it has also been reported (Yingling *et al.* 1992) that a short-acting agent (i.e., succinylcholine) may be administered during tracheal intubation because it is expected to be cleared during the surgical approach time, returning to normal status before reaching the critical stages of the surgery. Our anesthesia protocol used cisatracurium only during induction, with none added for maintenance. In addition, sevoflurane could restrain FMEPs, so the sevoflurane MAC was limited to <0.5 , which guaranteed the validity of the FMEP proce-

dure. Finally, protection of the FN requires cooperation of all involved, including neurosurgeons, nurses, anesthesiologists, and electrophysiologists.

CONCLUSION

Despite the advances in microsurgical techniques, the application of IONM could prove to be a valuable technique for achieving optimal microsurgical resection of large VSs while maintaining the anatomical integrity and function of the FN.

REFERENCES

- 1 Acioly MA, Liebsch M, de Aguiar PHP, Tatagiba M (2013). Facial nerve monitoring during cerebellopontine angle and skull base tumor surgery: a systematic review from description to current success on function prediction. *World Neurosurg.* **80**(6): e271–300.
- 2 Ansari SF, Terry C, Cohen-Gadol AA (2012). Surgery for vestibular schwannomas: a systematic review of complications by approach. *Neurosurg Focus.* **33**(3): E14.
- 3 Fenton JE, Chin RYK, Shirazi A, Fagan PA (1999). Prediction of postoperative facial nerve function in acoustic neuroma surgery. *Clinical Otolaryngology & Allied Sciences.* **24**(6): 483–486.
- 4 Franco-Vidal V, Nguyen DQ, Guerin J, Darrouzet V (2004). Delayed facial paralysis after vestibular schwannoma surgery: role of herpes viruses reactivation—our experience in eight cases. *Otology & Neurotology.* **25**(5): 805–810.
- 5 Grant GA, Rostomily RR, Kim DR, Mayberg MR, Farrell D, Avelino A, Duckert LG, Gates GA, Winn HR (2002). Delayed facial palsy after resection of vestibular schwannoma. *J Neurosurg.* **97**(1):93–96.

- 6 Gurgel RK, Dogru S, Amdur RL, Monfared A (2012). Facial nerve outcomes after surgery for large vestibular schwannomas: do surgical approach and extent of resection matter? *Neurosurg Focus*. **33**(3): E16.
- 7 Hillman T, Chen DA, Arriaga MA, Quigley M (2010). Facial nerve function and hearing preservation acoustic tumor surgery: Does the approach matter? *Otolaryngology--Head and Neck Surgery*. **142**(1): 115–119.
- 8 House JW, Brackmann DE (1985). Facial nerve grading system. *Otolaryngology--head and neck surgery*. **93**(2): 146.
- 9 Koos WT, Matula C, Lang J (2002). *Color Atlas of Microneurosurgery of Acoustic Neurinomas*. Thieme, 326 pages.
- 10 Kuhn MA, Nayak S, Camarena V, Gardner J, Wilson A, Mohr I, Chao MV, Roehm PC (2012). A cell culture model of facial palsy resulting from reactivation of latent herpes simplex type I. *Otology & Neurotology*. **33**(1): 87–92.
- 11 Lefaucheur J-P, Neves DO, Vial C (2009). Electrophysiological monitoring of cranial motor nerves (v, vii, ix, x, xi, xii). *Neuro-Chirurgie*. **55**(2): 136–41.
- 12 Moskowitz N, Long DM (1991). Acoustic Neurinomas. Historical Review of a Century of Operative Series. *Neurosurgery Quarterly*. **1**(1): 2–18.
- 13 Myrseth E, Pedersen PH, Møller P, Lund-Johansen M (2007). Treatment of vestibular schwannomas. Why, when and how?. *Acta Neurochirurgica*. **149**(7): 647–660.
- 14 Ojemann RG (2001). Retrosigmoid approach to acoustic neuroma (vestibular schwannoma). *Neurosurgery*. **48**(3): 553–558.
- 15 Oh T, Nagasawa DT, Fong BM, Trang A, Gopen Q, Parsa AT, Yang I (2012) Intraoperative neuromonitoring techniques in the surgical management of acoustic neuromas. *Neurosurg Focus*. **33**(3): E6.
- 16 Quesnel AM, McKenna MJ (2011). Current strategies in management of intracanalicular vestibular schwannoma. *Current Opinion in Otolaryngology & Head and Neck Surgery*. **19**(5): 335–340.
- 17 Rabelo FM, Russo A, Sequino G, Piccirillo E, Sanna M (2011). Analysis of hearing preservation and facial nerve function for patients undergoing vestibular schwannoma surgery: the middle cranial fossa approach versus the retrosigmoid approach—personal experience and literature review. *Audiology and Neurotology*. **17**(2): 71–81.
- 18 Samii M, Gerganov VM, Samii A (2010). Functional outcome after complete surgical removal of giant vestibular schwannomas: Clinical article. *Journal of Neurosurgery*. **112**(4): 860–867.
- 19 Rahimpour S, Friedman AH, Fukushima T, Zomorodi AR (2016). Microsurgical resection of vestibular schwannomas: complication avoidance. *Journal of Neuro-Oncology*. **130**(2): 367–375.
- 20 Thakur JD, Khan IS, Shorter CD, Sonig A, Gardner GL, Guthikonda B, Nanda A (2012). Do cystic vestibular schwannomas have worse surgical outcomes? Systematic analysis of the literature. *Neurosurg Focus*. **33**(3): E12.
- 21 Wiet RJ, Mamikoglu B, Odom L, Hoistad DL (2001). Long-term results of the first 500 cases of acoustic neuroma surgery. *Otolaryngology-Head and Neck Surgery*. **124**(6): 645–651.
- 22 Youssef AS, Downes AE (2009). Intraoperative neurophysiological monitoring in vestibular schwannoma surgery: advances and clinical implications. *Neurosurg Focus*. **27**(4): E9.
- 23 Yingling CD, Gardi JN (1992). Intraoperative monitoring of facial and cochlear nerves during acoustic neuroma surgery. *Otolaryngologic Clinics of North America*. **25**(2): 413–448.