

Rare cause of non-healing foot wound – acral lentiginous melanoma

Alena GERŠLOVA^{1,2}, Andrea POKORNA³, Alena ŠTUKAVCOVA⁴, Lenka VEVERKOVA¹

1 1st Surgical Department, St. Anne's University Hospital, Masaryk University Faculty of Medicine, Brno, Czech Republic

2 Outpatient Wound Healing Center and Surgical Unit, Břeclav Hospital, Břeclav, Czech Republic

3 Department of Nursing, Masaryk University Faculty of Medicine, Brno, Czech Republic

4 Department of Dermatology, Uherské Hradiště Hospital, Uherské Hradiště, Czech Republic

Correspondence to: Alena Geršlova, MD
Pekařská 664/53
656 91 Brno, Czech Republic.
E-MAIL: alena.gerslova@fnusa.cz

Submitted: 2015-11-06 Accepted: 2015-12-06 Published online: 2016-02-28

Key words: **diagnostic techniques; examination; foot; malignant melanoma; ulcer; wound**

Neuroendocrinol Lett 2016; **37**(1):12–17 PMID: 26994380 NEL370116C02 © 2016 Neuroendocrinology Letters • www.nel.edu

Abstract

The etiology of skin integrity disorders of the lower extremities can be very diverse. In addition to common diagnoses such as venous ulcers with ischemic etiology, decubitus ulcers and diabetic foot syndrome, ulceration of a malignant etiology must also be considered. Malignant melanoma is one of the most dangerous forms of skin cancer and, although rare, may cause foot lesions. The most frequently encountered type of melanoma on acral parts of the limbs is the rare acral lentiginous variant, which only occurs in 2–10% of all melanoma types. Clinical manifestation ranges from cutaneous surface erosion to ulceration with surrounding hyperkeratosis, which can cause considerable differential diagnostic difficulties in the management of patients with non-healing foot wounds. This paper aims to present a clear case study of a Caucasian female with chronic leg ulceration that resulted in a final diagnosis of malignant acral lentiginous melanoma. Supplemental theoretical information regarding the diagnosis and treatment of malignant melanoma has also been included in the report. Malignant acral lentiginous melanoma is a rare cause of non-healing wounds, but it must be considered in cases with long-term healing complications. Precise diagnostic deliberation is crucial in the management and treatment of all chronic and long-term non-healing lesions, and appropriately performed biopsies are essential to determine whether malignancy is the primary cause.

Abbreviations:

MM - Malignant Melanoma
ALM - Acral Lentiginous Melanoma
PET - Positron Emission Tomography
HIV - Human Immunodeficiency Virus
UVR - Ultraviolet Radiation

INTRODUCTION

Malignant melanoma (MM) is one of the most dangerous forms of skin cancer. It arises from the neoplastic proliferation of melanocytes (pigment-forming cells), which primarily occurs in the eye (e.g. the uvea, ciliary body, conjunctiva), the meninges and mucous membranes. MM is most common in middle age; the median age at diagnosis is 57 years and the average median mortality is 67 years (Vojáčková *et al.* 2012). The worldwide incidence of MM is continuously increasing and the number of reported cases doubles every 10 years. The current incidence in the Czech Republic is roughly 15 new melanoma cases per 100,000 inhabitants. Despite increasing incidence of MM in adults, melanoma remains rare in children and adolescents, who collectively represent 1–5% of all melanoma cases (Vojáčková *et al.* 2012). The exact cause of MM is not yet known. The most significant risk factor for MM is exposure to ultraviolet radiation (UVR) in the form of sunlight. The current classification of cutaneous malignant melanoma distinguishes between 4 principle types (Bristow *et al.* 2010). Acral lentiginous melanoma (ALM) is one type of malignant melanoma; it is a rare melanoma variant in the Caucasian population (2–10%), but it is the most commonly reported type of melanoma in the African American population (Barnhill *et al.* 2004). It characteristically presents in areas lacking hair follicles; i.e. the palms and soles, under the nails, and on mucous membranes – particularly the mouth and genitals (Cascinelli *et al.* 1994). Clinical manifestation begins as irregular mottled surface pigmentation which spreads invasively to deeper cutaneous structures; thus, ostensible surface lesions can reach considerable thickness (Wolff *et al.* 2005). Formations may present with fine desquamation and more or less apparent infiltration, or as small tumors with or without (amelanotic) pigmentation. Mechanical loading frequently results in surface erosion or ulceration of acral areas. This is followed by slight weeping or bleeding at the tumor border, which is usually surrounded by a thick horny layer (marginal callus). If growing under the fingernail, ALM may initially present as minor bleeding, which can lead to considerable differential diagnostic difficulties. Differential diagnosis should exclude hemorrhage, hemangioma, pyogenic granuloma, onychomycosis, granulation tissue (caro luxurians), melanocytic nevi, and plantar warts (Bristow *et al.* 2010). In many cases, repeated biopsies are required for early diagnosis. Although localized lower limb melanoma typically has a better prognosis, pedal melanoma is generally associated with poorer prognosis and survival. This necessitates a specific approach regarding prevention, diagnosis and treatment (Sanlorenzo *et al.* 2015). ALM is widely regarded as prognostically unfavorable and risky. Below, we present a case report involving a female patient who was treated at our clinic for a non-healing foot wound that was diagnosed as a malignant melanoma.

CASE REPORT

A Caucasian female born in 1936 was first treated at our surgical outpatient clinic in July 2011; she was 75 years of age at the time. She was then referred to a dermatology outpatient clinic for a chronic lesion on the plantar surface of the right foot, which was located under the first metatarsal head.

Clinical assessment and treatment (July 2011)

The patient presented with cutaneous surface excoriation and clear vesicles with no signs of retention or inflammation. A preliminary excision of the described lesion, which had been present for 3 months and did not respond to topical therapy, was performed at the dermatology outpatient clinic. Histological findings included ulceration without tumor infiltration and dominant reactive proliferative changes in the area of examination. The patient reported treatment for arterial hypertension (with antihypertensives being her only routine medication) and past treatment for gastroduodenitis, which was asymptomatic at the time of examination. She had undergone a cholecystectomy and hysterectomy with bilateral adnexectomy for uterine myoma (at 52 years of age). The patient stated that she had never smoked and only consumed alcohol on occasion. Our outpatient surgical clinic performed an X-ray examination of the right lower limb with no findings of osteolysis or other skeletal pathology. Lower limb pulsation was well-palpable bilaterally during clinical examination and no neurological sensitivity was noted. Therapy was initiated with a moist wound healing preparation, but the patient did not return for further treatment or check-ups. Instead, she elected to continue treatment at a private surgical outpatient clinic near her residence where (according to subsequent patient substantiated documentation) she underwent further local treatment for the ulceration and 2 excisions due to wound stagnation. The first ulcer excision occurred in January 2012 (following approximately 6 months of treatment) with histological findings of epidermal vesicles and massive hyperkeratosis. The upper dermis demonstrated edematous saturation with vascularized granulation tissue and chronic inflammatory infiltrate deposits. The wound was further treated locally with all common symptoms of secondary intention healing process. In May 2012 a second excision was performed with the following histological findings: acanthotic hyperkeratosis of the epidermis with an intraepidermal bullous defect; necrotic detritus, fibrin, and polymorphonuclears in the deep dermis; mixed cellularization and granulation tissue reparation. Epidermal pseudoepitheliomatous hyperplasia with acantholysis was observed in the vicinity of the lesion – reparation apparently corresponded to the post-traumatic process. The excision was complete.

Clinical assessment and treatment (July 2012)

The patient returned to the authors' surgical outpatient clinic 1 year later (July 2012). The wound had remained

stagnant in the form of intermittent excoriation of hyperkeratotic tissue, as well as cicatricial tissue from previous excisions. Signs of darker skin tones that had not been present previously were observed in the area; the differential diagnosis included hematoma, and pigmentation (Figure 1). Due to stagnation and occasional bleeding from the wound (Figure 2), an additional excision was performed in October 2012 with a finding of malignant melanoma (MM). A histological exam confirmed acral lentiginous melanoma (ALM) with dermal invasion and significant accompanying lymphocytic infiltrates, fibrosis, and mild pigment formation. The tumor extended to both lateral excision margins (Figures 3 and 4). One margin showed distinct perivascular reticular dermis invasion alongside sweat gland ducts, and nearly reaching the adipose tissue. According to commonly used classification (Clemente *et al.* 2001) the findings were evaluated as Breslow 1 mm, Clark IV. The examined portion of the tumor showed no ulceration (the tumor was covered with a thick *stratum corneum*) with minimal mitotic activity. Tumor thickness is the most significant long-term prognostic factor, which determines the radicality of surgery and indicates potential adjuvant therapies. The higher the Breslow value, the poorer the melanoma prognosis. Specialized

care was deemed necessary and, following consultations with practitioners from the Masaryk Memorial Cancer Institute (a comprehensive cancer center) in Brno, Czech Republic, the patient was placed in the care of the melanoma outpatient clinic for further examination and treatment. The oncology department performed a radical excision of healthy tissue, a PET scan showed no hypermetabolic deposits of suspected malignancy, and a histological examination was sentinel node negative.

DISCUSSION

In terms of the long-term treatment process of the described patient, it is possible to discuss the impact of an unclear diagnosis at the start of the therapeutic process and the risk of incorrect sampling for histological examination. The fact that the patient changed her attending physician and, for a certain period of time, was not monitored by a doctor with a long-term overview of the situation, were certainly contributing factors. One may, perhaps, argue the impact of patient (non) compliance stemmed from the feeling that moist wound healing therapy had been ineffective. In reality, a tumor can present on clinically normal skin as a result of congenital or acquired melanocytic nevi, and

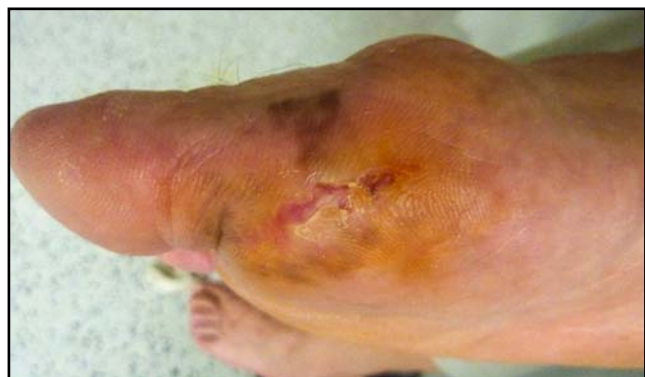

Fig. 1. Malignant acral lentiginous melanoma, under the first metatarsal head of the right foot (July 2012). (photo: authors' archive)

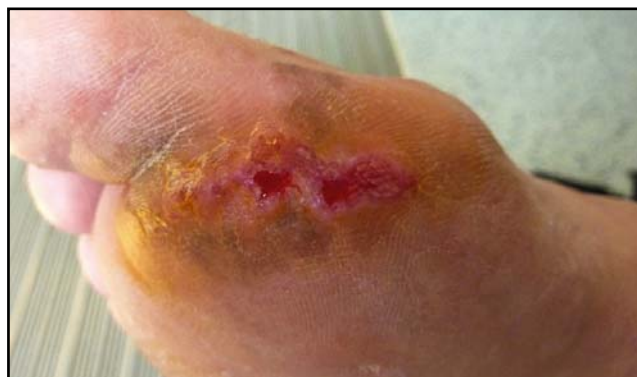

Fig. 2. Malignant acral lentiginous melanoma, under the first metatarsal head of the right foot (October 2012). (photo: authors' archive)

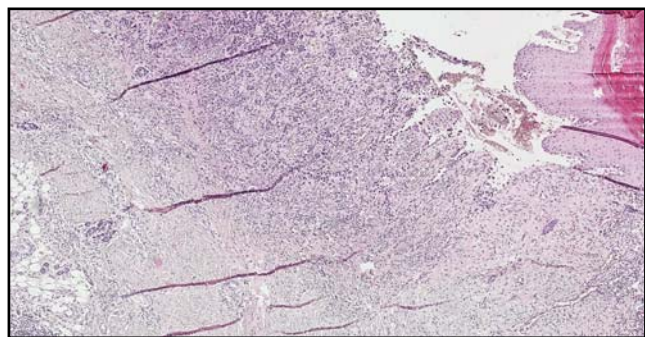


Figure 3. Histological slide following excision of the lesion. Cross-section on the right of the epidermis that is partially artificially separated, tumor infiltrates in the dermis; spindle tumor cells in the deep dermis that extend to the adipose tissue border.

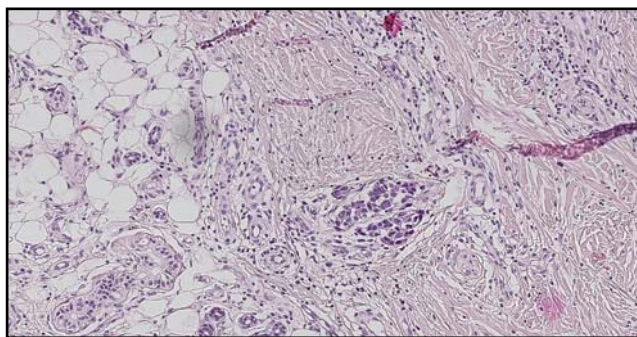


Figure 4. Histological slides following excision of the lesion. Spindle tumor details are described in Figure 3.

atypical (dysplastic) nevi or lentigo maligna deposits in particular (Elwood and Jopson 1997; Veierød *et al.* 2003). Patient age should also be considered in cases of suspected melanoma, because the average age at the time of ALM diagnosis is between 60 and 70 years (Swartz 2014). However, the patient did not mention the presence of pigmented nevi in the given area, nor did the dermatology clinic reports describe unequivocal pigment deposits in the area of chronic excoriation. According to published literature, *de novo* occurrence of ALM is also possible in healthy looking skin (Bristow *et al.* 2010). The Ultraviolet B (UVB) component of radiation (which induces a number of pathological cutaneous processes such immunosuppressive effects, the formation of free oxygen radicals and DNA melanocyte impairment) is primarily responsible for its carcinogenic effect (Lebwohl *et al.* 2014). In contrast, the negative effect of UVB radiation on non-exposed parts of the body (e.g. the soles of the feet) has not been fully proven (Bristow *et al.* 2010). Vulnerable population groups for MM development also include individuals with genetically conditioned skin phototypes I and II. ALM, however, is also associated with darker skin types (Bristow *et al.* 2010). According to the dermatologist report, our patient was phototype III. Familial predisposition is a significant risk factor for disease development. Genetic disorders include Familial Atypical Multiple Mole and Melanoma (FAMMM) syndrome, dysplastic nevi syndrome, and xeroderma pigmentosum (Braun-Falco *et al.* 2001). Further risks can include >50 acquired nevi, large congenital nevi, and dysplastic nevi, as well immunosuppression due to medications or diseases (e.g. HIV and hematological malignancies). The patient presented in our case report did not have a positive family history, nor any of the above risk factors, and these factors significantly affected the potential for early detection of suspicious oncological disease. The attending physician used the most common forms of clinical investigation. Clinical diagnosis of melanoma is still based on the fundamental ABCDE parameters of pigmented lesions: Asymmetry (asymmetrical appearance), Borders (border irregularity), Color (irregular color), Diameter (>6mm), and

Enlargement (over time). This checklist facilitates early distinguishing of superficial spreading melanomas from benign pigmented manifestations (Abbasi *et al.* 2004). However, use of the ABCDE system for plantar and nail pigmented lesions has been questioned by several authors (Metzger *et al.* 1998; Albreski and Sloan 2008; Bristow and Acland 2008). According to available sources, the CUBED examination (Table 1) is an alternative system (Bristow *et al.* 2010). Given that the patient had no pigment deposits in the early stages of non-healing, dermoscopy (a basic diagnostic method for nevi risk) was not performed. A dermoscopic examination is now an integral part of primary skin examinations for patients with pigmented nevi or suspected melanoma. It is a rapid, non-invasive method that enables accurate differentiation of individual lesion characteristics, which results in more accurate diagnoses of clinically unclear deposits (Bafounta *et al.* 2001). Dermoscopy as an effective differential diagnostic method has also been recommended by other authors, and its efficacy has been verified both in a prospective study of 200 patients with 224 acral pigmented lesions (Elwan *et al.* 2015), and a retrospective study of 257 white patients with a retrospective analysis of 360 dermoscopic images of acral melanocytic lesions (Wawrzynkiewicz *et al.* 2013). Efficient use of a dermoscope depends upon the training and experience of the attending dermatologist and, as previously mentioned, the presence of at least some cutaneous affections that suggest the presence of melanocytes (see the reference to the absence of nevi in the described case report). Clinical examination must also consider the patient history (e.g. changes in pre-existing pigmented lesions or their formation in adulthood) and diagnosis must be subsequently verified or ruled out via histopathological examination. According to Elwana *et al.* (2015) a properly conducted dermoscopic examinations can reduce the number of biopsies performed. ALM treatment involves radical surgical removal. Prognosis is generally very poor and the primary determinant is the presence or absence of lymph node involvement, especially sentinel nodes. It is necessary to reiterate that compliance was low in the described patient and the physician was unable to continuously monitor her status. The issue of atypical non-healing wounds is very relevant; this has been made evident by a workshop organized at the European Wound Management Association (EWMA) Conference in 2013 and previously published works (Rayner *et al.* 2009; Shelling *et al.* 2010). Economic burden is another issue (Sen *et al.* 2009) for patients and healthcare systems alike, and it impacts both the treatment process and patient compliance. The quality of life of patients and their families is another significant factor (Rayner *et al.* 2009; Sen *et al.* 2009; Shelling *et al.* 2010). Effective treatment processes require a multidisciplinary approach and a variety of non-invasive (e.g. ultrasonography, ankle brachial index, X-ray) and invasive diagnostic modalities.

Tab. 1. The CUBED acronym for foot melanoma identification (Bristow *et al.* 2010).

C	Colored lesions where any part is not skin color.
U	Uncertain diagnosis. Any lesion that does not have a definite diagnoses.
B	Bleeding lesions on the foot or under the nail, whether the bleeding in direct bleeding or oozing of fluid. This includes chronic "granulation tissue".
E	Enlargement or deterioration of lesion or ulcer despite therapy.
D	Delay in healing of any lesion beyond 2 months.

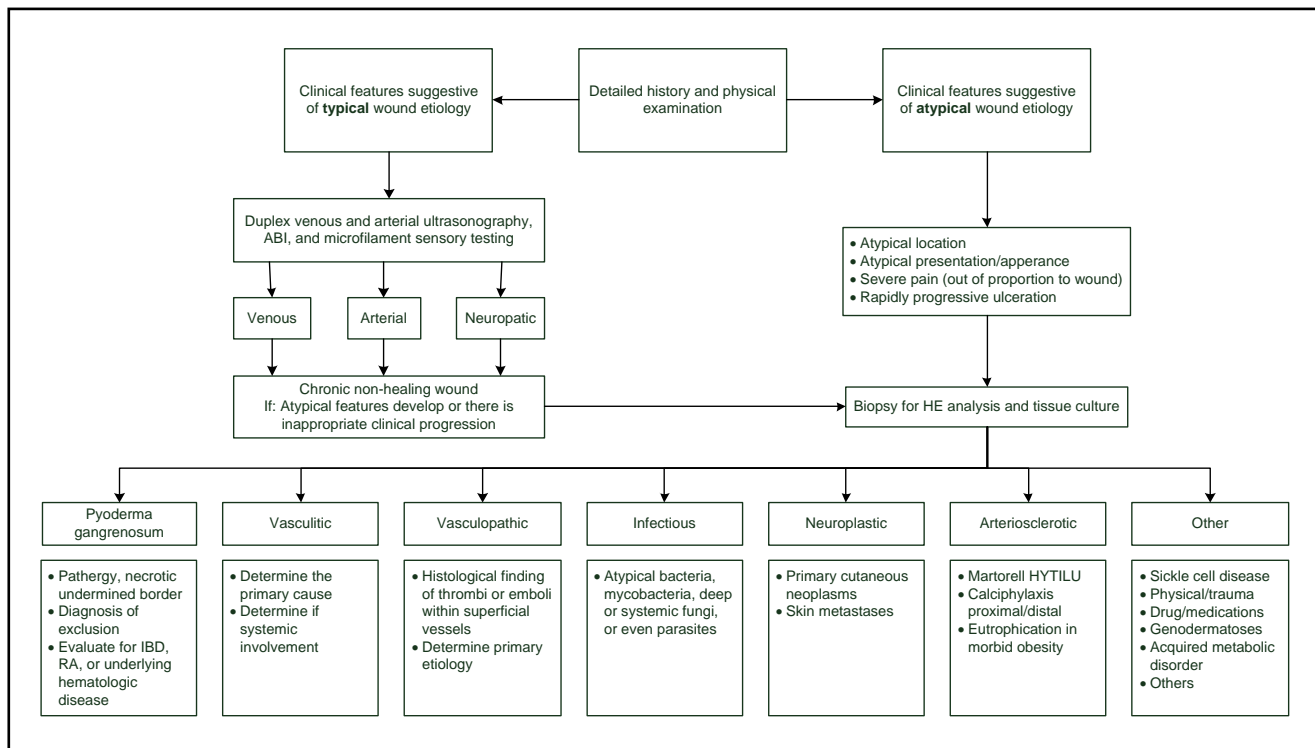


Figure 5. Diagnostic algorithm for atypical non-healing wounds (adapted from Shelling *et al.* 2010).

ties (Smith *et al.* 1998; Dean 2008). Regardless of which identification system is used (ABCDE or CUBED), simple algorithms should be implemented during the differential diagnosis process. Therefore, we would like to take the liberty of suggesting an algorithm for the diagnosis of atypical non-healing wounds in clinical practice (Figure 5) which has been adapted from cited expert sources (Mekkes *et al.* 2003; Shiman *et al.* 2009; Shelling *et al.* 2010).

CONCLUSION

Effective differential diagnosis of non-healing foot wounds is multifactorial. Physician erudition and experience, potential diagnostic modalities, patient compliance, and patient ability to describe their difficulties and wound manifestations, all play an important role in the process. Our case report describes the negative potential impact of patient non-compliance, which manifested as the legitimate, but not quite purposeful, selection of another practitioner. Ultimately, this resulted in a delayed primary oncological diagnosis. Timely and appropriate diagnosis of chronic wound etiology clearly leads to a greater chance of healing and, in case of malignancy, is a prerequisite measure that could be life-saving. For these reasons, it is essential that all chronic wounds (not only those of the lower limbs) be approached with caution and that the cause be identified as quickly as possible through consultations within a multidisciplinary team.

REFERENCES

- 1 Abbasi NR, Shaw HM, Rigel DS, Friedman RJ, McCarthy WH, Osman I *et al.* (2004). Early diagnosis of cutaneous melanoma: revisiting the ABCD criteria. *JAMA*. **292**: 2771–2776
- 2 Albreški D, Sloan SB (2009). Melanoma of the feet: misdiagnosed and misunderstood. *Clin Dermatol*. **27**: 556–563. doi: 10.1016/j.clindermatol.2008.09.014.
- 3 Bafounta ML, Beauchet A, Aegerter P, Saiag P (2001). Is dermoscopy (epiluminescence microscopy) useful for the diagnosis of melanoma? Results of a meta-analysis using techniques adapted to the evaluation of diagnostic tests. *Arch Dermatol*. **137**: 1343–1350.
- 4 Barnhill RL, Piepkorn M, Busam KJ (2004). *Pathology of Melanocytic Nevi and Malignant Melanoma*. 2nd ed. New York: Springer Verlag, p. 238–394.
- 5 Braun-Falco O, Plewig G, Wolff H (2001). Maligní melanóm. *Dermatológia a Venerológia*. [(Malignant Melanoma: Dermatology and Venerology) (In Slovak language with English abstract.]] Martin: Osveta, 2001, p. 1236–1247.
- 6 Bristow IR, Acland K (2008). Acral lentiginous melanoma of the foot: a review of 27 cases. *J Foot Ankle Res*. **1**: 11. doi: 10.1186/1757-1146-1-11.
- 7 Bristow IR, de Berker DA, Acland KM, Turner RJ, Bowling J (2010). Clinical guidelines for the recognition of melanoma of the foot and nail unit. *J Foot Ankle Res*. **3**: 25. doi: 10.1186/1757-1146-3-25.
- 8 Cascinelli N, Zurrida S, Galimberti V, Bartoli C, Bufalino R, Del Prato I *et al.* (1994). Acral lentiginous melanoma: a histological type without prognostic significance. *J Dermatol Surg Oncol*. **20**: 817–822.
- 9 Clemente C, Cook M, Ruitter D (2001). *Histopathologic Diagnosis of Malignant Melanoma*. World Health Organization Melanoma Programme Publications, Milan: Trezzano. No. 5.
- 10 Dean SM (2008). Atypical Ischemic Lower Extremity Ulcerations: A Differential Diagnosis. *Vasc. Med*. **1**: 47–54.

- 11 Elwan NM, Eltawy RA, Elfar NN, Elsakka OM (2015). Dermoscopic features of acral pigmented lesions in Egyptian patients: a descriptive study. *Int J Dermatol*. doi: 10.1111/ijd.12882. [Epub ahead of print]
- 12 Elwood JM, Jopson, J (1997). Melanoma and sun exposure: an overview of published studies. *Int J Cancer*. **73**: 198–203.
- 13 Lebwohl MG, Heymann WR, Berth-Jones J, Coulson I (2014). Malignant Melanoma. *Treatment of Skin Disease*. 4th ed. New York: Elsevier Saunders, p. 438–443.
- 14 Mekkes JR, Loots MA, Van Der Wal AC, Bos JD (2003). Causes, Investigation and Treatment of Leg Ulceration. *Br J Dermatol*. **3**: 388–401.
- 15 Metzger S, Ellwanger U, Stroebel W, Schiebel U, Rassner G, Fierlbeck G (1998). Extent and consequences of physician delay in the diagnosis of acral melanoma. *Melanoma Res*. **8**: 181–186. doi: 10.1097/00008390-199804000-00014.
- 16 Rayner R, Carville K, Keton J, Prentice J, Santamaria N (2009). Leg Ulcers: Atypical Presentations and Associated Comorbidities. *Wound Practice and Research*. **4**: 168–184.
- 17 Sanlorenzo M, Osella-Abate S, Ribero S, Marengo F, Nardò T, Fierro MT (2015). Melanoma of the lower extremities: foot site is an independent risk factor for clinical outcome. *Int J Dermatol*. **9**: 1023–1029. doi: 10.1111/ijd.12730. Epub 2015 Feb 6.
- 18 Sen CK, Gordillo GM, Roy S, Kirsner R, Lambert L, Hunt TK *et al.* (2009). Human Skin Wounds: A Major And Snowballing Threat To Public Health And The Economy. *Wound Repair Regen*. **6**: 763–771.
- 19 Shelling ML, Federman, DG, Kirsner RS (2010). Clinical Approach to Atypical Wounds With a New Model for Understanding Hypertensive Ulcers. *Arch. Dermatol*. **9**: 1026–1029. doi:10.1001/Archdermatol.2010.213.
- 20 Shiman MI, Pieper B, Templin TN, Birk TJ, Patel AR, Kirsner RS (2009). Venous Ulcers: A Reappraisal Analyzing The Effects Of Neuropathy, Muscle Involvement, And Range Of Motion Upon Gait And Calf Muscle Function. *Wound Repair Regen*. **2**: 147–152.
- 21 Smith ES, Feldman SR, Fleischer AB, Leshin B, McMichael A (1998). Characteristics Of Office-Based Visits For Skin Cancer: Dermatologists Have More Experience Than Other Physicians In Managing Malignant And Premalignant Skin Conditions. *Dermatos. Surg*. **9**: 981–985.
- 22 Swartz MH (2014). *Textbook of Physical Diagnosis: History and Examination*. New York: Elsevier Health Sciences. 7th ed. 793 p.
- 23 Veierød MB, Weiderpass E, Thörn M, Hansson J, Lund E, Armstrong B *et al.* (2003). A prospective study of pigmentation, sun exposure, and risk of cutaneous malignant melanoma in women. *J Natl Cancer Inst*. **95**: 1530–1538.
- 24 Vojáčková N, Kružicová Z, Vrbová L, Sečnicková Z (2012). Maligní melanom. [(Malignant Melanoma) (In Czech with English abstract.)] *Česká dermatovenerologie*. **2**: 76–84.
- 25 Wawrzynkiewicz M, Wozniak W, Wojas-Pelc A, Chlebick M, Ogiela J (2013). Dermoscopic pattern analysis of acral melanocytic nevi. *Przeg Lek*. **11**: 911–915.
- 26 Wolff K, Johnson RA, Suurmond D (2005). Acral Lentiginous Melanoma. In: Wolff K *et al.* *Fitzpatrick's Color Atlas And Synopsis of Clinical Dermatology*. 5th ed, New York:Mc Graw Hill education, p. 326–328.