

Thyroid hormones are needed to sustain “inappropriately” normal TSH during non-thyroidal illness syndrome: a clinical observation in severely ill patients with primary hypothyroidism

Joaquin LADO-ABEAL^{1,2}

¹ Division of Endocrinology, Department of Medicine, Texas Tech University Health Sciences Center School of Medicine, Lubbock, Texas, USA

² Unidade de Enfermedades Tiroideas e Metabolicas (UETeM), University of Santiago de Compostela School of Medicine, Santiago de Compostela, Spain

Correspondence to: Joaquin Lado-Abeal, MD., PhD.
Division of Endocrinology, Department of Internal Medicine
Texas Tech University Health Sciences Center-School of Medicine
3601 4th Street, MS 9410, Lubbock, TX, 79430, USA.
TEL: +1 806 743-3155; FAX: +1 806 743-3148; E-MAIL: joaquin.lado@ttuhsc.edu

Submitted: 2015-02-04 *Accepted:* 2015-02-20 *Published online:* 2015-02-27

Key words: **non-thyroidal illness syndrome; hypothyroidism; TSH; deiodinase; thyroid hormone replacement**

Neuroendocrinol Lett 2015; **36**(1):41–47 PMID: 25789598 NEL360115A08 ©2015 Neuroendocrinology Letters • www.nel.edu

Abstract

OBJECTIVES: Non-thyroidal illness syndrome (NTIS) is a form of hypothyroidism that occurs during illness. NTIS is characterized by low thyroid hormones (TH) level in the serum and tissues, with normal serum TSH levels that are considered “inappropriately” normal. The mechanisms responsible for a lack of increase in serum TSH during NTIS are unknown. However, a decreased expression of hypothalamic TRH has been documented in deceased humans with NTIS. It has been suggested that pro-inflammatory cytokines are responsible for the inhibition of TRH release. If a similar TSH response occurs in severely ill patients with primary hypothyroidism has not been reported.

DESIGN: Seven severely ill patients with unknown or poorly treated primary hypothyroidism are presented. Serum TSH and TH were measured at admission and during TH replacement.

SETTING: Tertiary university hospital.

RESULTS: Besides suffering severe illness, patient’s serum TSH was high and decreased once TH replacement was given. Levothyroxine administration was enough to down regulate TSH secretion. Serum reverse T3 (rT3) was normal or high and showed further elevation with stepwise increase in levothyroxine doses.

CONCLUSIONS: The thyroid axis inhibitory feedback system is fully preserved in primary hypothyroidism during severe illness. In NTIS, serum TSH levels remain within normal limits because the supply of TH to TRH neurons is sustained normally. Pro-inflammatory cytokines does not play a major role inhibiting TRH release during NTIS associated to primary hypothyroidism. D3 activity increases in humans with severe illness, a mechanism behind the increased requirements in TH replacement to achieve normal serum TH.

Abbreviations:

- BID - bis in die (twice per day)
- BMI - body mass index
- BP - blood pressure
- CABG - coronary artery bypass graft
- CT - computerized tomography
- D1 - type I deiodinase
- D2 - type II deiodinase
- D3 - type III deiodinase
- EKG - electrocardiogram
- ER - emergency room
- ICU - intense care unit
- mcg - microgram
- NTIS - Non-thyroidal illness syndrome
- rT3 - reverse of T3
- T4 - thyroxine
- T3 - triiodothyronine
- TH - thyroid hormone
- TRH - thyroid releasing hormone
- TSH - thyroid stimulating hormone

INTRODUCTION

Non-thyroidal illness syndrome (NTIS) is a cause of transient hypothyroidism commonly observed in hospitalized patients that is characterized by low levels of triiodothyronine (T3), and in severe illness also by low thyroxine (T4), in the serum and tissues, and normal or even low serum levels of TSH (De Groot 1999; Wartofsky & Burman 1982). The mechanisms preventing the increase in serum TSH during NTIS are not well characterized (Boelen *et al.* 2011), although studies in humans attribute a major role to the hypothalamus (Van den Berghe *et al.* 1998). Accordingly, patients who died after severe protracted illness associated with NTIS showed lower expression levels of TRH in the hypothalamus than subjects with normal serum thyroid hormone levels at death (Fliers *et al.* 1997). Furthermore, TRH administration to patients with NTIS restored normal serum TSH levels excluding a major pituitary dysfunction (Van den Berghe *et al.* 1998). Since inflammatory cytokines inhibits hypothalamic TRH expression in

rodents (van Haasteren *et al.* 1994), a similar effect has been suggested in human (Bartalena *et al.* 1998; De Groot 1999).

Tissues from humans suffering NTIS showed lower thyroid hormone levels than those without NTIS (Arem *et al.* 1993). A similar result was obtained in domestic pigs under septic shock for 48 hours (Castro *et al.* 2013). However, and contrary to peripheral tissues, T3 levels in the pigs brain were not different between control and NTIS septic animals (Castro *et al.* 2013). T3 reaches central nervous system neurons from two sources, directly from the circulation and from the astrocytes where T4 is converted into T3 by type II deiodinase (D2). Because septic shock induced NTIS is a condition of very low serum T3, maintaining normal levels of T3 in the brain should result from an increase of activity in astrocytes D2. In fact, in rodents under inflammatory conditions D2 expression and activity increases in leptomeninges, brain blood vessels, and choroid plexus (Wittmann *et al.* 2014). Also, D2 expression increases in tanycytes, glial cells lining the floor and ventrolateral walls of the third ventricle that regulate access of peripheral signal into the hypothalamus and cerebrospinal fluid (Fekete *et al.* 2004).

All together, these observations indicate that NTIS is a condition of peripheral hypothyroidism secondary in part to a decreased conversion of T4 into T3 – due to an inhibition of type I deiodinase (D1) activity mainly in liver and kidney, and to an increase in type III deiodinase (D3) – that nevertheless is associated with an increase in D2 expression and activity in astrocytes and tanycytes, a mechanism that sustain T3 supply to central nervous system neurons (Fekete & Lechan 2014). A group of patients with untreated or poorly treated primary hypothyroidism admitted in a tertiary hospital due to severe illness are presented. Patient's initial thyroid hormone profile and TSH response to thyroid hormone replacement helped to clarify the hypothalamic-pituitary response during NTIS in humans, in support of the above mentioned patho-physiological mechanisms.

PATIENTS

Seven patients with severe illness and hypothyroidism admitted at a tertiary hospital intense care unit (ICU).

Patient 1

A 59 year-old male presented to the emergency room (ER) complaining of lower back pain after suffering an accidental fall. Patient phenotype suggested hypothyroidism that was confirmed by a thyroid hormone test (Table 1). His body mass index (BMI) at admission was 26.32 kg/m². Levothyroxine replacement was started at 50 mcg per day. On hospitalization day 4, the patient presented with abdominal distension secondary to colon dilation. A colonoscopy guided decompression was unsuccessful and he developed a cecum perfora-

Tab. 1. Serum thyroid hormone profile of patients at admission.

Patient	1	2	3	4	5	6	7
TSH (mUI/L)	64.25	14.78	430.3	54.26	15.56	12.09	3.17
TT4 (mcg/dL)	1.53						
FT4 (ng/dL)	1.07	0.54	0.15	0.84	1.23	1.31	
FT3 (pg/mL)	1.34		1		1.71	2.81	
TPO Abs (IU/mL)	+	+	-		+	-	-
Tg Abs (IU/mL)	+	+	-	+	+	-	-

TSH: thyroid stimulating hormone (normal range – NR: 0.27–4.20 mUI/L); TT: total thyroxine (NR:5.10–14.0 mcg/dL); FT4: free T4 (NR: 0.93–1.70 ng/dL); FT3: free T3 (NR: 2.30–4.20 pg/mL); TPO Abs: anti-thyropoxidase antibodies, Tg Abs: ani-thyroglobulin antibodies.

tion that required an ileocecal resection and anastomosis of the ileum to the transverse colon. Three days later the patient suffered an acute myocardial infarction with a ventricular ejection fraction of 30%. Patient's clinical course was further complicated by a gastrointestinal hemorrhage and a large pericardial effusion that required pericardiocentesis. At hospitalization day 18, the endocrinology division was consulted for management of hypothyroidism. Patient required hemodynamic support with continuous dobutamine and/or norepinephrine infusion; no improvement was observed and patient was pronounced deceased on hospitalization day 31. Serum TSH and thyroid hormone levels as well as thyroid hormone replacement given during hospitalization are shown in Figure 1. After the perforation of the colon and acute myocardial infarction, serum levels of TSH were higher than at diagnoses even though the patient was receiving TH replacement (Figure 1). After 12 days of increasing doses of levothyroxine and 10 mcg of liothyronine BID given intravenously, serum TSH levels were nearly normalized by the time of death. On hospitalization day 23, serum rT3 was 15 ng/dL (normal range – nr: 11–32) and serum FT4 0.52 ng/dL. Normal serum FT4 levels were achieved after 10 days of a progressive increase in levothyroxine dosage and normal serum FT3 levels were achieved 48 hours after liothyronine replacement began (Figure 1). Serum TSH and FT4 values presented negative correlation (Pearson $r=-0.86$) that however did not achieve statistical significance ($p=0.06$). Correlation between TSH and FT3 was weaker (Pearson $r=-0.65$, $p=0.23$). T3 replacement was stopped 48 hours before death that caused a decrease in serum FT3 levels without increase in serum TSH.

Patient 2

This patient was a 70 year-old female diagnosed with hypothyroidism four months prior to current admission, during a hospitalization for a triple coronary artery bypass graft, where she was treated with levothyroxine 50 mcg per day. On present admission, patient complained of anorexia for three months with 7 kg weight loss, fatigue, dyspnea, ortopnea and lower extremity edema. Her BMI was 21.2 kg/m². Patient symptoms were initially attributed to an asthma exacerbation and she received 20 mg of intravenous methylprednisolone every 12 hours during the first 48 hours of hospitalization (Figure 2A). Further evaluation showed severe aortic insufficiency secondary to endocarditis caused by *Enterococcus faecalis* that required replacement of the aortic valve. At admission, a serum thyroid hormone profile showed that patient continued hypothyroid (Table 1) and levothyroxine was increased from 50 to 75 mcg per day (Figure 2A). Four days later, serum TSH remained elevated (22.65 mUI/L) and at day 5, when aortic valve replacement was performed, levothyroxine was further increased to 100 mcg per day, liothyronine was started at a dose of 10 mcg per day,

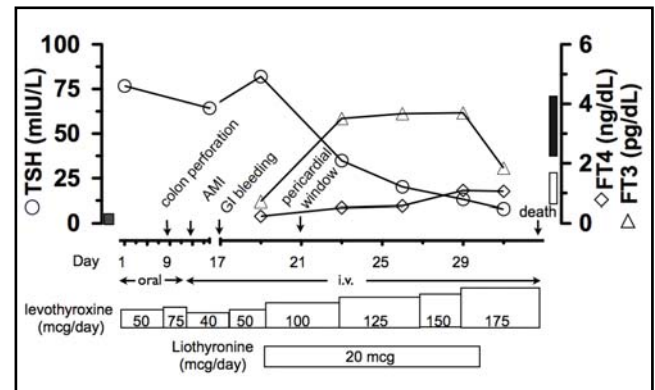


Fig. 1. Changes in serum TSH, free T4 (FT4) and free T3 (FT3) levels of patient 1 under thyroid hormone replacement during admission. AMI: acute myocardial infarct; GI: gastrointestinal. Dark bar close to right Y axis represent range of normal serum TSH; bars close to left Y axis represent normal serum FT4 (white) and FT3 (black).

and one dose of amiodarone was given (150 mg/i.v.). At day 9, serum TSH level was 42.92 mUI/L (Figure 2A), and serum rT3 was 41 ng/dL. The progressive increase in serum TSH during the first 8 days of hospitalization was associated with a decrease in serum FT4 levels. Levothyroxine was further increased to 150 mcg for 3 days and finally to 175 mcg, and liothyronine was increased to 10 mcg BID, with a progressive decrease in serum TSH levels (Figure 2A). At hospitalization day 15, patient was discharged from the hospital.

Patient 3

A 30 year-old female with congenital hypothyroidism, who presented with a three weeks history of severe left lower abdominal pain. The pain was caused by a massive hematoma located around a previously transplanted kidney that occurred after a left femoral catheter placement. Patient had end stage renal disease since childhood secondary to post-streptococcal glomerulonephritis and underwent two renal transplants that rejected. One month before admission she was hospitalized for endocarditis. Patient had clinical features of cretinism and had a long history of noncompliance with thyroid hormone replacement (Table 1). BMI was 23.33 kg/m². A left nephrectomy with evacuation of perinephric hematoma and left artery aneurism repair were delayed for 15 days because of severe hypothyroidism. At hospitalization day 12 serum rT3 was 50 ng/dL. Patient was discharged to home at hospitalization day 21. Serum TSH and thyroid hormone levels as well as thyroid hormone replacement given during hospitalization are showed in Figure 2B.

Patient 4

A 62 year-old male who presented acute dyspnea and globus pharyngis. He had complained of hoarseness for six months. A neck CT showed a large glottic and supraglottic mass obliterating the airway and a nodular goiter. His BMI was 25 kg/m². A tracheostomy was per-

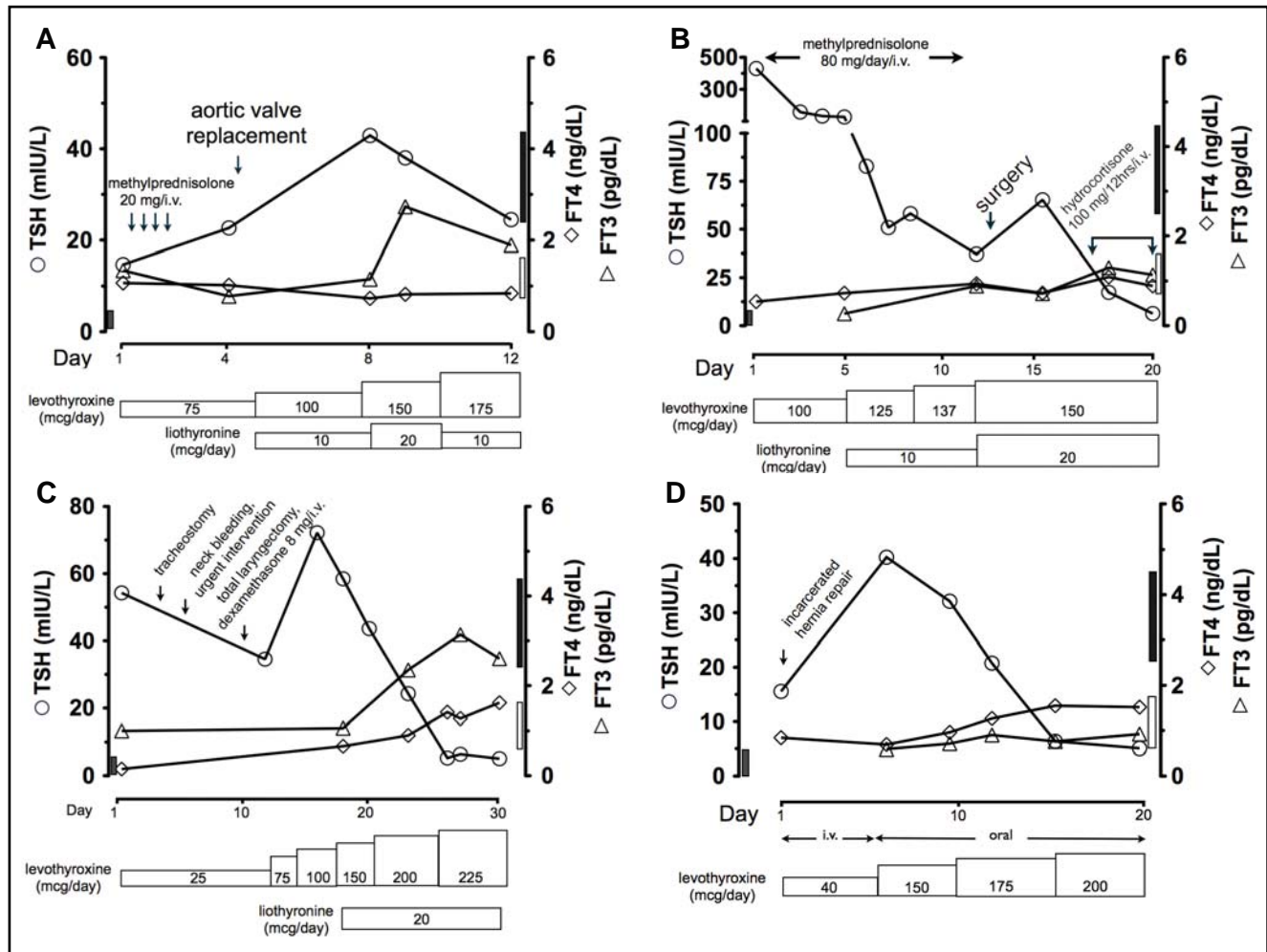


Fig. 2. Changes in serum TSH, FT4 and FT3 levels under thyroid hormone replacement during admission in patients 2 (A), 3 (B), 4 (C) and 5 (D).

formed initially to relieve the obstruction complicated by a left vocal cord paralysis. Two days latter the patient had a massive bleed from the thyroid bed that required urgent intervention. At hospitalization day 10, a total laryngectomy and bilateral modified radical neck dissection with bilateral internal jugular vein ligation was performed. The pathology analysis revealed a primary laryngeal squamous cell carcinoma invading the thyroid gland and cervical lymph nodes. On admission, a thyroid hormone profile revealed severe hypothyroidism with positive anti-thyroglobulin antibodies (Table 1). The primary care team started levothyroxine replacement but at hospitalization day 18 the endocrinology division was consulted for management because serum TSH was 72.2 mUI/L. Serum TSH and thyroid hormone levels as well as replacement doses of levothyroxine and liothyronine are shown in Figure 2C. At hospitalization day 18, while the patient was on levothyroxine 100 mcg/day/i.v., the serum rT3 was 11 ng/dL and FT4 0.66 ng/dL; at day 23, while the patient was receiving levothyroxine 200 mcg/day/i.v., the serum rT3 increased up to 21 ng/dL and FT4 was 0.9 ng/dL. Patient was discharged at day 34 and he continued treatment as outpatient.

Patient 5

A 72 year-old female with autoimmune hypothyroidism admitted to the hospital with right lower abdominal pain. Two months prior, she had presented with congestive heart failure secondary to coronary artery disease that required a triple coronary artery bypass graft (CABG). At that time, she was on levothyroxine 150 mcg per day and serum TSH and FT4 were within normal range. After CABG she suffered a non-sustained ventricular tachycardia and atrial fibrillation with extensive diffuse bilateral brain embolism involving both cerebral and cerebellar hemispheres. Continuous renal replacement therapy was necessary for 3 days as a result of an acute kidney injury. At hospitalization on day 16 serum TSH was slightly elevated (8.96 mUI/L) and FT4 low (0.69). Patients was discharged home but two months later she returned to the ER with dyspnea. She had an infection at the saphenous vein graft sites and was started on iv antibiotics and vacuum assisted closure therapy. A chest CT scan showed a left pleural effusion with exudative characteristics that required a chest tube placement for drainage. She had stopped levothyroxine and serum TSH was 54.4 mUI/L, FT4

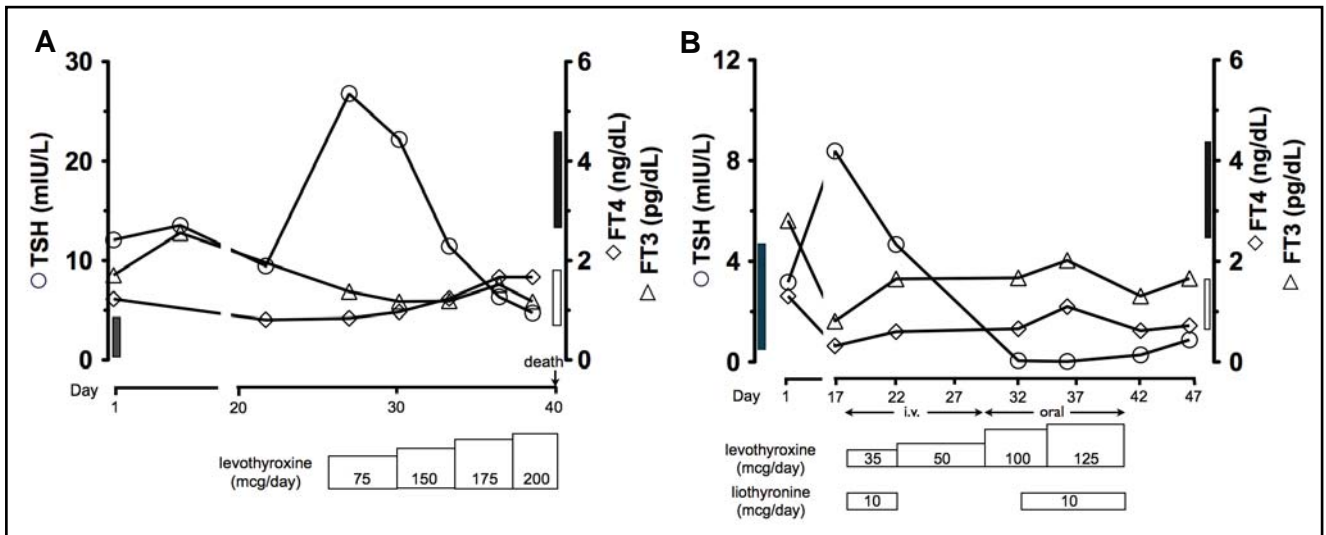


Fig. 3. Patients 6 (A) and 7 (B) serum levels of TSH, FT4 and FT3 during hospital admission.

0.65 ng/dL and FT3 0.7 pg/dL. Levothyroxine, at a dose of 75 mcg per day orally, was started during this hospitalization. Once again, the patient was discharged home, and two days later returned to the ER complaining of right lower abdominal pain. An incarcerated incisional hernia was noted requiring surgical intervention. At this admission her BMI was 30 kg/m², serum TSH was 15.56 mUI/L and FT4 0.84 ng/dL (Table 1). Intravenous levothyroxine replacement at 40 mcg per day was initiated. Five days latter the serum TSH was 40.25 mUI/L, FT4 0.69 ng/dL, and FT3 0.59 pg/dL. Endocrinology was consulted and replacement with oral levothyroxine at 150 mcg per day was started and progressively increased during hospitalization. By day 5 on this regimen, serum rT3 was 77 ng/dL. Serum TSH and thyroid hormone levels as well as levothyroxine replacement doses during the last hospitalization are shown in Figure 2D. At hospitalization day 25, patient was discharged to a skilled nursing facility

Patient 6

A 54 year-old female with stage 4 squamous cell carcinoma of lung presented to the ER complaining of palpitations. Patient received chemotherapy until 3 months before admission without clinical improvement, after which she started a holistic and naturopathic treatment for cancer in Mexico. She had been on different thyroid hormone replacement regimens for years due to non-autoimmune hypothyroidism but stopped two weeks before admission. Her BMI was 20 kg/m², heart rate was regular at 160 bpm and BP 93/70 mmHg. Other remarkable findings were elevated white cell count (19.82 k/mcL), normocytic and normochromic anemia, hyponatremia (129 mmol/L), and hypercalcemia (11.8 mg/dL). An EKG showed atrial-flutter with a 2:1 conduction. A chest CT scan showed a large heterogeneous necrotic mass in the left hemithorax with

cavitation, encasement of the thoracic aorta, main and left pulmonary artery, and left main bronchus, with extension of the mass through the anterior left chest wall and involvement of multiple anterior ribs and the pectoral muscle, as well as occlusion of the left subclavian and left internal jugular veins. Patient was started on iv antibiotics and supportive measures without significant improvement in her clinical status, and died on hospitalization day 44. On admission her serum TSH was 12.09 mUI/L, FT4 1.23 ng/dL and FT3 1.71 pg/dL (Table 1), but thyroid hormone replacement was not started by the primary team until hospitalization day 26 when serum TSH was 26.81 mUI/L, FT4 0.84 ng/dL and FT3 1.38 pg/dL (Figure 3A). Serum rT3 was 37 ng/dL after five days on 75 mcg followed by two days on 150 mcg of levothyroxine, rT3 was 43 ng/dL after four days on 175 mcg of levothyroxine and it was 67 ng/dL after two days on 200 mcg of levothyroxine.

Patient 7

A 33 year-old male who presented with generalized weakness, nausea and vomiting for 2 weeks. He reported feeling unwell for the last four months and complained of excessive thirst, drinking up to 15 liters of water per day. His BMI was 20 kg/m². Positive finding on physical exam were hypotension, tachycardia and mild edema in the lower extremities and abdominal wall. Initial laboratory tests showed severe hyponatremia (114 mmol/L), mild hypokalemia (3.4 mmol/L) and metabolic acidosis with elevated anion gap. Urine sodium and urine osmolarity were both low. An initial 8 AM serum cortisol, TSH and thyroid hormone levels were within normal range (Table 1). At hospitalization day 16, mild hypothyroidism was noticed (TSH 8.38 mUI/L, FT4 0.31 ng/dL, FT3 0.81 pg/dL, negative thyroperoxidase and thyroglobulin antibodies) and thyroid hormone replacement was initiated (Figure 3B). The patient's

condition worsened progressively with anasarca, oligo/anuria, severe hypotension, with pulmonary edema, mild pulmonary hypertension, intrahepatic cholestasis, gastrointestinal bleeding, encephalopathy, and malnutrition. Despite extensive diagnostic workup, the primary cause of patient's condition remained unknown. Fortunately, he spontaneously improved over a period of weeks and was discharged after 54 days in the hospital. Serum TSH and thyroid hormone levels as well as thyroid hormone replacement are shown in Figure 3B.

DISCUSSION

Seven patients with severe illness are presented. Two patients had unknown hypothyroidism before admission, four patients were already known to have hypothyroidism but had received inadequate hormonal replacement or were not compliant, and one patient developed hypothyroidism during hospitalization as part of NTIS. The patients with primary hypothyroidism presented with elevated serum TSH levels despite having a clinical condition severe enough to trigger NTIS. Usually, patients with such conditions present low serum thyroid hormone levels with "inappropriately" normal or even low serum TSH that results from a decreased production in hypothalamic TRH (Fliers *et al.* 1997). The mechanisms responsible for a decrease in TRH expression and release from the hypothalamus during NTIS remain unknown although a prevalent hypothesis is an inhibitory effect of pro-inflammatory cytokines on hypothalamic paraventricular nucleus where the hypophysiotropic TRH neurons are located (Bartalena *et al.* 1998; De Groot 1999; Fekete & Lechan 2014).

The present clinical observations show that thyroid hormones play the main role in preventing the elevation of serum TSH during NTIS. Besides suffering severe illnesses, the six patients with poorly treated or untreated primary hypothyroidism had elevated or even extremely high serum TSH levels that decreased once thyroid hormone replacement was given. These observations dispute a major role of pro-inflammatory cytokines in preventing an increase in TSH during NTIS (Bartalena *et al.* 1998). Also, activation of the adrenal axis or administration of exogenous steroids do not seem to have a significant role in preventing the increase in serum TSH during NTIS (De Groot 1999) since even very high doses of powerful glucocorticoids given for several days to some patients did not have a relevant effect in decreasing TSH levels.

The mechanisms controlling the expression and secretion of TRH and TSH remain fully functional during severe illness. Accordingly, the administration of thyroid hormones to very sick patients with untreated hypothyroidism and elevated serum TSH levels, caused the expected inhibitory feedback effect on TSH release. It can be inferred also that the transport and action of thyroid hormones at the hypothalamus and pituitary

gland remains completely functional during severe illness. In this regard, patient 7 is very informative since on admission the thyroid hormone profile was normal but 17 days later presented mild hypothyroidism for which he received levothyroxine for a short period that resulted in suppression of serum TSH. The expression of D2 in tanycytes increases during illness (Fekete *et al.* 2004), a mechanism that could maintain or even increase T3 supply to the hypothalamus preventing an increase in TRH expression and release during NTIS induced peripheral hypothyroidism (Fekete *et al.* 2004). However an increase in hypothalamic D2 activity during NTIS has not been reported (Castro *et al.* 2013; Mebis *et al.* 2009). A recent study in pigs showed that NTIS caused by 48 hours of septic shock lead to a profound decrease in T4 and T3 levels in serum and peripheral tissues; however no differences in brain T3 levels were noticed between septic and control pigs (Castro *et al.* 1999) indicating that the brain was not hypothyroid during a short period of septic shock induced NTIS. Similarly, a study in rabbits showed that T3 levels in the hypothalamus of prolonged critically ill animals were not lower than controls despite lower serum T4 and T3 levels in critically ill animals (Mebis *et al.* 2009). The pig study showed also that hypothalamic D3 activity was higher in septic than control pigs (Castro *et al.* 2013). It seems then, that during NTIS the brain triggers a response directed to maintain thyroid hormone supply that involves an increase in D2 activity (enzyme that converts T4 into T3) and, at the same time, to prevent hyperthyroidism through an increase in D3 activity (enzyme that converts T4 into rT3 and T3 into T2).

Our clinical observation does not have the power to discriminate which of the two hormones, T4 or T3 exerts the main negative feedback on TSH release during NTIS. However, the fact that patients 5 and 6 nearly normalized serum TSH and patient 7 presented low serum TSH besides low serum FT3 levels while receiving only levothyroxine replacement, indicate that replacement with T4 is enough to down regulate TSH secretion.

Serum rT3 was elevated in patients 2, 3, 5, and 6 or in relation to values of serum FT4 (patients 1 and 4), an observation that confirms the increase of D3 activity *in vivo* during severe illness in humans. Particularly illustrative are serum rT3 levels in patients 4 and 6, showing a remarkable increase with increases doses of levothyroxine replacement. The high requirements of thyroid hormone replacement doses necessary to normalize serum FT4 and FT3 in sick hypothyroid patients seems a consequence of an elevated D3 activity.

In conclusion, the present clinical observation showed that during severe illness: 1) the expected physiological TRH-TSH response to hypothyroidism is maintained, 2) thyroid hormones are necessary to prevent increase in serum TSH, and T4 administration is enough to regulate serum TSH levels, 3) thyroid hormone transport and effects on hypothalamus and pitu-

itary are also maintained, 4) the increase in D3 activity has patho-physiological impact causing an increase in thyroid hormone replacement dose requirements to achieve normalization of serum thyroid hormone levels. Finally, these observations suggest that during NTIS, the hypothalamus triggers a response that include an increase in D2 activity, to sustain an adequate supply of thyroid hormone besides the low levels of T4 and T3 in serum and peripheral tissues.

REFERENCES

- 1 Arem R, Wiener GJ, Kaplan SG, Kim HS, Reichlin S, Kaplan MM (1993). Reduced tissue thyroid hormone levels in fatal illness. *Metabolism*. **42**: 1102–1108.
- 2 Bartalena L, Bogazzi F, Brogioni S, Grasso L, Martino E (1998). Role of cytokines in the pathogenesis of the euthyroid sick syndrome. *Eur J Endocrinol*. **138**: 603–614.
- 3 Boelen A, Kwakkel J, Fliers E (2011). Beyond low plasma T₃: local thyroid hormone metabolism during inflammation and infection. *Endocr Rev*. **32**: 670–693.
- 4 Castro I, Quisenberry L, Calvo RM, Obregon MJ, Lado Abeal J (2013). Septic shock non-thyroidal illness syndrome causes hypothyroidism and conditions for reduced sensitivity to thyroid hormone. *J Mol Endocrinol*. **50**: 255–266.
- 5 De Groot LJ (1999). Dangerous dogmas in medicine: the nonthyroidal illness syndrome. *J Clin Endocrinol Metab*. **84**: 151–164.
- 6 Fekete C, Gereben B, Doleschall M, Harney JW, Dora JM, Bianco AC, *et al.* (2004). Lipopolysaccharide induces type 2 iodothyronine deiodinase in the mediobasal hypothalamus: implications for the nonthyroidal illness syndrome. *Endocrinology*. **145**: 1649–1655.
- 7 Fekete C, Lechan RM (2014). Central regulation of hypothalamic-pituitary-thyroid axis under physiological and pathophysiological conditions. *Endocr Rev*. **35**: 159–194.
- 8 Fliers E, Guldenaar SE, Wiersinga WM, Swaab DF (1997). Decreased hypothalamic thyrotropin-releasing hormone gene expression in patients with nonthyroidal illness. *J Clin Endocrinol Metab*. **82**: 4032–4036.
- 9 Mebis L, Debaveye Y, Ellger B, Derde S, Ververs EJ, Langouche L, *et al.* (2009). Changes in the central component of the hypothalamus-pituitary-thyroid axis in a rabbit model of prolonged critical illness. *Crit Care*. **13**: R147.
- 10 Van den Berghe G, de Zegher F, Baxter RC, Veldhuis JD, Wouters P, Schetz M, *et al.* (1998). Neuroendocrinology of prolonged critical illness: effects of exogenous thyrotropin-releasing hormone and its combination with growth hormone secretagogues. *J Clin Endocrinol Metab*. **83**: 309–319.
- 11 van Haasteren GA, van der Meer MJ, Hermus AR, Linkels E, Klootwijk W, Kaptein E, *et al.* (1994). Different effects of continuous infusion of interleukin-1 and interleukin-6 on the hypothalamic-hypophysial-thyroid axis. *Endocrinology*. **135**: 1336–1345.
- 12 Wartofsky L, Burman KD (1982). Alterations in thyroid function in patients with systemic illness: the 'euthyroid sick syndrome'. *Endocr Rev*. **3**: 164–203.
- 13 Wittmann G, Harney JW, Singru PS, Nouriel SS, Reed Larsen P, Lechan RM (2014). Inflammation-inducible type 2 deiodinase expression in the leptomeninges, choroid plexus, and at brain blood vessels in male rodents. *Endocrinology*. **155**: 2009–2019.