

# Epicardial left ventricular lead for cardiac resynchronization therapy

Marián FEDORCO<sup>1</sup>, Alan BULAVA<sup>2,3</sup>, Petr ŠANTAVÝ<sup>4</sup>, Miloš TÁBORSKÝ<sup>1</sup>

<sup>1</sup> University Hospital Olomouc, Department of Cardiology, Czech Republic

<sup>2</sup> České Budějovice Hospital, Department of Cardiology, Czech Republic

<sup>3</sup> University of South Bohemia in České Budějovice, Faculty of Health and Social Studies, Czech Republic

<sup>4</sup> University Hospital Olomouc, Department of Cardiosurgery, Czech Republic

*Correspondence to:* Assoc Prof. Alan Bulava, MD., PhD.  
České Budějovice Hospital, Department of Cardiology  
B. Němcové 54, 370 01 České Budějovice, Czech Republic.  
E-MAIL: alanbulava@seznam.cz

*Submitted:* 2014-08-20    *Accepted:* 2014-09-08    *Published online:* 2014-09-15

*Key words:*                    **cardiac resynchronization therapy; endocardial; epicardial; coronary sinus; pacing leads**

Neuroendocrinol Lett 2014; **35**(Suppl. 1):34–39    PMID: 25433352    NEL350914R01    © 2014 Neuroendocrinology Letters • [www.nel.edu](http://www.nel.edu)

## Abstract

Cardiac resynchronization therapy is now recognized as an effective and safe therapeutic modality in heart failure patients and leads to a reduction in mortality and morbidity. Today, transvenous implantation is considered to be the gold standard for lead placement. However, transvenous LV lead implantation fails in 2–10% of patients undergoing the implantation procedure. In these cases surgical LV lead implantation is preferred. The present article reviews LV pacing lead implantation strategies in cases where standard transvenous implantation failed.

## Abbreviations:

CRT	- cardiac resynchronization therapy
ECG	- electrocardiography
EF	- ejection fraction
HF	- heart failure
LBBS	- left bundle branch block
LV	- left ventricle
MRI	- magnetic resonance imaging
SPECT	- single photon emission computed tomography
QLV	- LV lead electrical delay
TDI	- tissue-doppler imaging

## INTRODUCTION

Cardiac resynchronization therapy (CRT) is currently recognized as an effective and safe therapeutic modality for heart failure (HF) patients who remain symptomatic despite optimal medical therapy, have left ventricular dysfunction and exhibit an intraventricular delay in the form of a wide QRS complex (Abraham and Hayes 2003). Randomized clinical trials show that CRT leads to a reduction in mortality and is associated with increased functional capacity, improved quality of life and a reduction in the hospitalization rate (Ansalone *et al.* 2002; Bleeker *et al.* 2006; Gras *et al.* 2007; Ypenburg *et al.* 2008a). Unfortunately, a significant proportion (from 30–40%) of HF patients does not respond to CRT and do not show any improvement in clinical status and cardiac function (Fung *et al.* 2004). A number of factors are related to the non-response phenomenon, includ-

ing suboptimal patient selection, non-optimal left ventricular (LV) lead placement, extensive myocardial scarring and sub-optimal device programming (Lambiase *et al.* 2004).

The primary hypothesis or target of CRT is restoration of coordinated myocardial contraction through biventricular pacing. The conventional approach has been to direct the left ventricular lead to the lateral or posterolateral wall. This strategy is based on the presumption that most patients indicated for CRT have a left bundle branch block (LBBB) and the last parts of the left ventricle to be activated are the lateral or posterolateral segments. Earlier studies have shown the hemodynamic benefits of this approach (Cazeau *et al.* 1996; Gras *et al.* 1998; Leclercq *et al.* 1998; Saxon *et al.* 1998; Auricchio *et al.* 1999a; Gras *et al.* 2002; Cleland *et al.* 2005). The optimal LV lead position can be defined as having the LV pacing lead coincident with the last activated segment of the left ventricle. In this position we can expect optimized hemodynamic performance and favorable long-term outcomes (Bleeker *et al.* 2006; Becker *et al.* 2007; Ypenburg *et al.* 2008b; Polasek *et al.* 2012). The three most important factors considered to be predictors of an optimal response to resynchronization are: (1) assessment of the last activated segment of the left ventricle, (2) presence of suitable coronary venous branches, and (3) location and quantification of myocardial scarring. The presence of suitable coronary sinus tributaries in the lead placement area is essential. The final position of the LV pacing lead depends on (1) the anatomy of the cardiac venous system, (2) performance and stability of the pacing lead, and (3) absence of phrenic nerve stimulation.

The present article reviews LV pacing lead implantation strategies in cases, where standard transvenous implantation failed.

## CONVENTIONAL CARDIAC RESYNCHRONIZATION THERAPY IMPLANTATION

The standard implantation procedure is performed in the electrophysiology lab using local anesthesia and antibiotic prophylaxis. The procedure consists of preparation of the device pocket (subcutaneous or subpectoral), fluoroscopy guided transvenous implantation of the right ventricular (septal or apical position) and right atrial (patients in sinus rhythm) leads and transvenous implantation of the LV lead, usually performed via the coronary sinus. Procedural success and feasibility depends on variations of coronary sinus and venous anatomy, technical aspects such as accessibility of the target vein, pacing threshold, lead stability, and phrenic nerve stimulation.

In daily clinical practice, the LV pacing lead is usually positioned as far as possible from the right ventricular pacing lead, commonly into the lateral or postero-lateral cardiac veins. A more sophisticated approach is to

use an integrated evaluation including an assessment of the venous anatomy before implantation, assessment of the last activated segments of the LV, and verifying the presence and extent of myocardial scarring to predict the maximal response rate.

## ASSESSMENT OF CARDIAC VENOUS ANATOMY

The most common approach for evaluation of cardiac venous anatomy uses fluoroscopy just prior to implantation of the LV pacing lead. Either with or without the use of a balloon occlusion catheter in the proximal coronary sinus, retrograde coronary sinus venography is obtained. Another method is visualization of the venous phase during coronary angiography of the left main artery. The cardiac venous anatomy can also be assessed with multi-detector row high-resolution computed tomography or magnetic resonance imaging.

## ASSESSMENT OF LATEST ACTIVATED SEGMENT OF THE LEFT VENTRICLE

We can use invasive or non-invasive techniques to assess the last activated segments of the LV. One of the invasive techniques involves assessing the LV lead electrical delay (QLV). This is done by measuring the difference between the onset of a surface ECG QRS event relative to the onset of this same QRS event measured on an intracardiac electrocardiogram. Longer QLVs indicate better lead placement, i.e. closer to the last activated regions of the LV and are associated with higher probabilities of a positive CRT response (Polasek *et al.* 2012). Several non-invasive imaging techniques have been proposed to identify the last activated areas. 3-D non-contact LV endocardial mapping provides exact characterization of the LV activation sequence, and different echocardiographic parameters like TDI (tissue-doppler imaging) or 2-D speckle tracking imaging and tagged magnetic resonance imaging can also be useful. MRIs can evaluate LV shortening in circumferential and longitudinal directions and/or thickening in the radial direction (Lambiase *et al.* 2004; Helm *et al.* 2005; Hummel *et al.* 2005; Lardo *et al.* 2005; Becker *et al.* 2007a,b; Ypenburg *et al.* 2008b). However, none of these techniques have proved to be clinically reproducible and effective in selecting CRT responders.

## ASSESSMENT OF LOCATION AND EXTENT OF MYOCARDIAL SCARRING

The evaluation of the location and extent of myocardial scarring is crucial for achieving highly favorable response rates. The implantation of an LV lead in an area with transmural myocardial scarring can result in a reduced or even a non-response to CRT. LV segments with a myocardial scarring, which can slow conduction, can be identified using 3-D non-contact LV endocar-

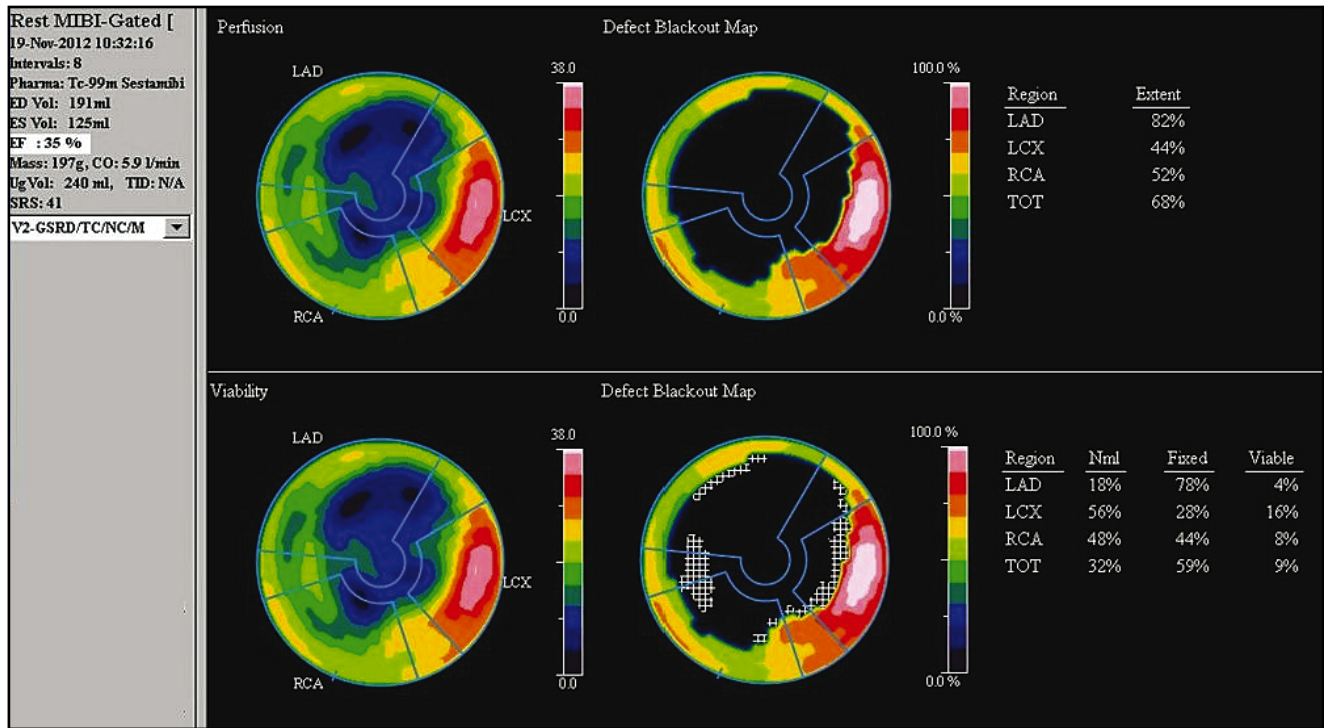


Fig. 1. Gated SPECT 3D images of endocardial surface silhouettes, demonstrating diffuse left ventricular hypokinesia with apical dyskinesia.

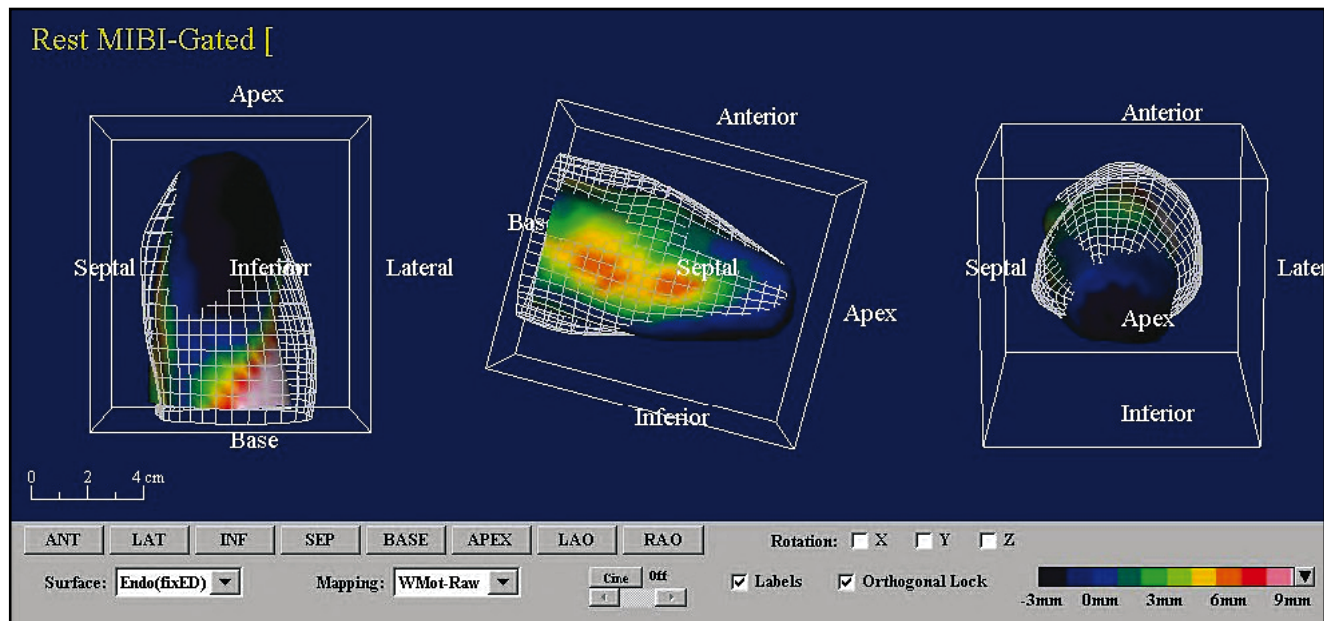


Fig. 2. Rest Tc-99m-sestamibi images shows severely reduced uptake of tracer in the apex, anterior wall and in the apical part of the lateral and septal wall. The extent of perfusion defect was 68% of the total left ventricle (upper row), the extent of non-viable myocardium was 59% of left ventricle (tracer uptake <50% of peak activity, lower row).

dial mapping systems. Other non-invasive imaging techniques provide information on myocardial scarring include MRI – magnetic resonance imaging, myocardial contrast echocardiography, and SPECT – single photon emission computed tomography (Figures 1, 2) (Hummel *et al.* 2005, Bulava and Lukl 2007, Ypenburg 2007b).

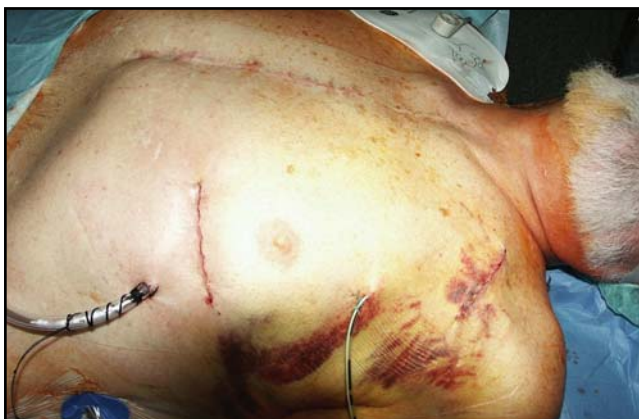### SURGICAL LEFT VENTRICULAR EPICARDIAL LEAD PLACEMENT TECHNIQUES

Transvenous implantation of LV pacing leads fail in 2–10% of patients undergoing CRT implantation. Failures are associated with the manual dexterity of the

surgeon, surgical experience, appropriate equipment and electrode selection, and use of novel methods for facilitating LV lead placement (angioplasty or stent implantation). Bulava *et al.* (2007) reported a 98% first-attempt success rate and the overall transvenous success rate, for CS lead placement, was 99%. Several factors can result in implantation failure. These factors include: (i) absence of a venous access (in cases of stenosis or occlusion of the subclavian vein), (ii) coronary sinus cannulation failure (prominent sub-eustachian or/and thebesian valve, right atrium dilatation), (iii) absence of suitable lateral coronary vein branches, (iv) lead instability, (v) unacceptable threshold, (vi) extensive LV myocardial scarring, and (vii) phrenic nerve stimulation. In these situations surgical LV lead implantation is preferred. Several surgical techniques have been proposed to implant LV pacing leads: mini-thoracotomy, video-assisted thoracoscopy, and robotically enhanced tele-manipulation systems. There are several different types of LV epicardial leads; all of them are steroid-eluting. They are classified based pacing mode as unipolar or bipolar, and by type of fixation as screw-in or suture fixation epicardial leads.

### MINI-THORACOTOMY

The procedure is performed in the operating room under general anesthesia and a beating heart. All patients have standard vital functions monitoring (ECG, pulse oximetry, capnometry, invasive arterial monitoring). After a standard single lumen intubation, the patient is placed in a supine position with the left side of the chest elevated. Using of the selective lung ventilation during the thoroscopic surgery is well known and very often described method. This method of lung ventilation should be beneficial during mini-invasive cardiac surgery (mini-thoracotomy), too. Next, a left lateral, mid-axillary mini-thoracotomy (4–8 cm) at the sight of the fourth or fifth intercostal space (Figure 3) is performed and the left lung is pushed back. The pericardium is

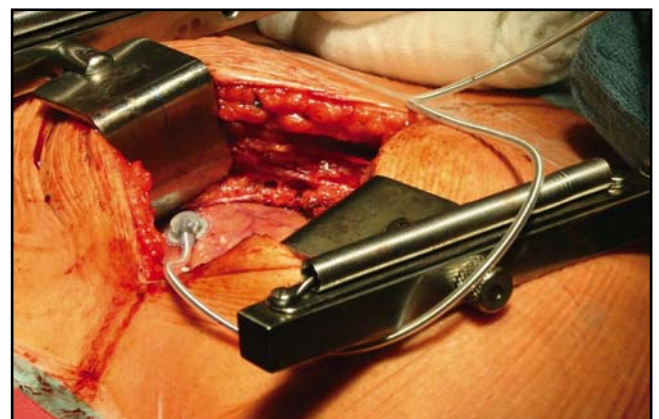


**Fig. 3.** Left lateral mini-thoracotomy in the fifth intercostal space. Figure depicts final state just after surgery. Chest tube is inserted below, pocket drainage above.

opened anterior to the phrenic nerve while maintaining a safe distance. Visual assessment or mapping of the left ventricle is used to determine the optimal pacing location and the epicardial pacing lead is then fixed to the target area (Figure 4), which is followed by pacing threshold, impedance and sensing measurements. The lead connector is brought through the intercostal space and then tunneled to the device pocket and connected to the pacemaker or defibrillator. The pericardium is partially closed, followed by standard wound closure.

### VIDEO-ASSISTED THORACOSCOPY APPROACH

The procedure is performed in the operating room under general anesthesia and on a beating heart. The patient is placed in a right-lateral decubitus position with the left side of the chest elevated to 50–70°. After deflation of the left lung, a port for the camera is inserted, usually, through the fourth intercostal space between the middle and posterior axillary line. A second flexible disposable instrumentation port is positioned in the fourth intercostal space on the anterior axillary line. The pericardium is opened anterior to the phrenic nerve while maintaining a safe distance. Once the lateral wall of the left ventricle is exposed and the marginal arteries identified, the epicardial pacing lead is inserted through the instrumentation port, positioned correctly and fixed to the target area. Pacing threshold, sensing and impedance measurements are then carried out. After removal of the ports, the proximal end of the epicardial lead is passed through the medial incision, tunneled to the device pocket and connected to the pacemaker or defibrillator. The thoroscopic surgery has some relative or absolute contraindications: (i) pericardial or pleural adhesions (history of inflammatory diseases, previous surgery), (ii) impossibility for selective lung ventilation and other. Using of the mini-thoracotomy approach is better and more safe technique in these cases.



**Fig. 4.** Left lateral mini-thoracotomy. A bipolar screw-in left ventricular lead is fixed to the target area.



## ROBOTICALLY ENHANCED TELE-MANIPULATION SYSTEMS

The procedure is performed in the operating room under general anesthesia and on a beating heart, with selective right lung intubation. The patient is positioned in a full posterolateral thoracotomy position and all standard vital functions are monitored. The robotic device consists of the surgeon's control console and the surgical arm unit that positions and directs the micro-instruments. The instruments are inserted into the chest cavity through two ports. A third port is used to insert the endoscope. The instruments are controlled by the surgeon. A camera port is placed in the seventh intercostal space on the posterior axillary line. The left and right console arms are positioned in the ninth and fifth intercostal space, respectively. A working port is inserted posterior to the camera port and is used for insertion of the lead and sutures. The robotic arms are used to fix the lead to the LV surface using either screw in fixation or suture fixation depending on lead type. The lead connector is covered and the lead is tunneled to the device pocket.

## COMPARISON OF THE STANDARD ENDOVASCULAR VERSUS SURGICAL APPROACH

Mair *et al.* (2005) reported on 80 patients with epicardial LV leads for biventricular pacing implanted using 3 different techniques (mini-thoracotomy, a video-assisted thoracoscopy approach and a robotically enhanced tele-manipulation system). They reported that acute and 3-month LV lead thresholds were satisfactory in 79 patients (99%). Two lead displacements were observed. Five patients who underwent the robotic procedure needed a conversion to thoracotomy because of a technical failure of the robotic system (2 patients) or massive pleural adhesions (3 patients). There were no severe adverse events related to any of the techniques used.

Garikipati *et al.* (2014) compared endovascular and epicardial groups in patients with heart failure. Epicardial leads were placed using a minimally invasive, robot-assisted thoracoscopic approach. The primary end point was a decrease in the LV end-systolic volume index at 6 months. The secondary end points included 30-day mortality rate, measures of clinical improvement, 1-year electrical lead performance, and 1-year survival rate. They concluded that there were no differences in echocardiographic and clinical outcomes.

Mair *et al.* (2005) reported that surgically placed epicardial leads had excellent long-term results and a lower LV-related complication rate compared to CS-leads. Additionally, they found that the mini-thoracotomy approach was a safe and reliable technique that offered 100% accuracy relative to lead placement on the intended target and could have potential benefits

as the primary implantation method for a substantial subset of patients.

On the other hand, Koos *et al.* (2004) found significantly different outcomes in patients who underwent a limited left thoracotomy ( $n=25$ ) compared to a coronary sinus approach ( $n=56$ ). After one year, patients who underwent surgical LV lead placement had less improvement in LV EF and peak functional capacity and worse survival. The finding that epicardial LV leads were more likely to be placed anteriorly may explain the reduction in ventricular remodelling seen in this study.

## OUR EXPERIENCE

In our hospital, implantation of left ventricular epicardial electrodes is carried out using mini-thoracotomy. Our data confirm that it is a safe and effective method for cases in which standard transvenous implantation failed. We found that pacing parameters were comparable with endocardial pacing and that the rate of response to resynchronization was also comparable with endocardial lead insertion (Fedorco *et al.* 2012).

## CONCLUSION

In conclusion, all three techniques for surgical epicardial LV lead implantation for biventricular pacing are feasible and safe. Each method allows optimal lead implantation under direct visualization and therefore can reduce the incidence of non-responders resulting from suboptimal lead placement. Assessment of the last activated areas, cardiac venous anatomy, and location and extent of myocardial scarring, prior to CRT device implantation, is crucial for maximal benefits from this therapy. Despite all the improvements in lead technology and implantation equipment, epicardial lead placement is still more invasive than transvenous placement. Because of longer recovery times and increased peri-operative complications, in conjunction with additional costs, transvenous lead placement should remain the first choice for properly selected patients requiring CRT.

## ACKNOWLEDGEMENT

This study was partially funded by the Faculty of Health and Social Studies, University of South Bohemia in České Budějovice (BOV 2012\_001).

## REFERENCES

- 1 Abraham WT, Hayes DL (2003). Cardiac resynchronization therapy for heart failure. *Circulation*. **108**: 2596–2603.
- 2 Ansalone G, Giannantoni P, Ricci R, Trambaiolo P, Fedele F, Santini M (2002). Dopplermyocardial imaging to evaluate the effectiveness of pacing sites in patients receiving biventricular pacing. *J Am Coll Cardiol*. **39**: 489–499.

- 3 Auricchio A, Klein H, Tockman B, Sack S, Stellbrink Ch, Neuzner J *et al.* (1999a). Transvenous biventricular pacing for heart failure: can the obstacles be overcome? *Am J Cardiol.* **83**(Suppl 2): 136–142.
- 4 Auricchio A, Stellbrink Ch, Block M, Sack S, Vogt J, Bakker P *et al.* (1999b). Effect of pacing chamber and atrioventricular delay on acute systolic function of paced patients with congestive heart failure. *Circulation.* **99**: 2993–3001.
- 5 Becker M, Franke A, Breithardt OA, Ocklenburg C, Kaminski T, Kramann R *et al.* (2007a). Impact of left ventricular lead position on the efficacy of cardiac resynchronization therapy: a two-dimensional strain echocardiography study. *Heart.* **93**: 1197–1203.
- 6 Becker M, Hoffmann R, Schmitz F, Hundemer A, Kuhl H, Schauerte P *et al.* (2007b). Relation of optimal lead positioning as defined by three-dimensional echocardiography to long-term benefit of cardiac resynchronization. *Am J Cardiol.* **100**: 1671–1676.
- 7 Bleeker GB, Bax JJ, Fung JW, van der Wall EE, Zhang Q, Schalij MJ *et al.* (2006). Clinical versus echocardiographic parameters to assess response to cardiac resynchronization therapy. *Am J Cardiol.* **97**: 260–263.
- 8 Bulava A, Lukl J (2007). Single-center experience with coronary sinus lead stability and long-term pacing parameters. *Europace.* **9**: 523–527.
- 9 Cazeau S, Ritter P, Lazarus A, Gras D, Backdach H, Mundler O *et al.* (1996). Multisite pacing for end-stage heart failure: early experience. *Pacing Clin Electrophysiol.* **19**: 1748–1757.
- 10 Cleland JG, Daubert JC, Erdmann E, Freemantle N, Gras D, Kappenberger L *et al.* (2005). Cardiac Resynchronization-Heart Failure (CARE-HF) Study Investigators. The effect of cardiac resynchronization on morbidity and mortality in heart failure. *N Engl J Med.* **352**: 1539–1549.
- 11 Fedorco M, Šantavý P, Bulava A, Marek D, Doupal V, Táborský M (2012). Střednědobá stabilita levokomorové epikardiální elektrody pro srdeční resynchronizační léčbu [Mid-term stability of left ventricle epicardial lead for cardiac resynchronization therapy]. [online] [cit. 2014-07-24]. Available from: <http://www.cksonline.cz/abstrakta/detail.php?p=detail&id=3817> (in Czech without English abstract)
- 12 Fung JW, Yu CM, Yip G, Zhang Y, Chan H, Kum CC *et al.* (2004). Variable left ventricular activation pattern in patients with heart failure and left bundle branch block. *Heart.* **90**: 17–19.
- 13 Garikipati Naga V, Mittal S, Chaudhry F, Musat DL, Sichrovsky T, Preminger M *et al.* (2014). Comparison of endovascular versus epicardial lead placement for resynchronization therapy. *Am J Cardiol.* **113**: 840–844.
- 14 Gras D, Mabo P, Tang T, Luttikhuis O, Chatoor R, Pedersen A *et al.* (1998). Multisite Pacing as a Supplemental Treatment of Congestive Heart Failure: Preliminary Results of the Medtronic Inc. InSync Study. *Pacing Clin Electrophysiol.* **21**: 2249–2255.
- 15 Gras D, Leclercq C, Tang ASL, Bucknall C, Luttikhuis HO, Kirstein-Pedersen A (2002). Cardiac resynchronization therapy in advanced heart failure the multicenter InSync clinical study. *Eur J Heart Fail.* **4**: 311–320.
- 16 Gras D, Bocker D, Lunati M, Wellens HJ, Calvert M, Freemantle N *et al.* (2007). Implantation of cardiac resynchronization therapy systems in the CARE-HF trial: procedural success rate and safety. *Europace.* **9**: 516–522.
- 17 Helm RH, Leclercq C, Faris OP, Ozturk C, McVeigh E, Lardo AC *et al.* (2005). Cardiac dyssynchrony analysis using circumferential versus longitudinal strain: implications for assessing cardiac resynchronization. *Circulation.* **111**: 2760–2767.
- 18 Hummel JP, Lindner JR, Belcik JT, Ferguson JD, Mangrum JM, Bergin JD *et al.* (2005). Extent of myocardial viability predicts response to biventricular pacing in ischemic cardiomyopathy. *Heart Rhythm.* **2**: 1211–1217.
- 19 Koos R, Sachweh J, Meuris B, Nollert G, Schmoeckel M, Schuetz A *et al.* (2004). Comparison of left ventricular lead placement via the coronary venous approach versus lateral thoracotomy in patients receiving cardiac resynchronization therapy. *Am J Cardiol.* **94**: 59–63.
- 20 Lambiase PD, Rinaldi A, Hauck J, Mobb M, Elliott D, Mohammad S *et al.* (2004). Non-contact left ventricular endocardial mapping in cardiac resynchronization therapy. *Heart.* **90**: 44–51.
- 21 Lardo AC, Abraham TP, Kass DA (2005). Magnetic resonance imaging assessment of ventricular dyssynchrony: current and emerging concepts. *J Am Coll Cardiol.* **46**: 2223–2228.
- 22 Leclercq C, Cazeau S, Le Breton H, Ritter P, Mabo P, Gras D *et al.* (1998). Acute hemodynamic effects of biventricular DDD pacing in patients with end-stage heart failure. *J Am Coll Cardiol.* **32**: 1825–1831.
- 23 Mair H, Sachweh J, Meuris B, Nollert G, Schmoeckel M, Schuetz A *et al.* (2005). Surgical epicardial left ventricular lead versus coronary sinus lead placement in biventricular pacing. *Eur J Cardiothor Surg.* **27**: 235–242.
- 24 Polasek R, Kucera P, Nedbal P, Roubicek T, Belza T, Hanuliakova J. *et al.* (2012). Local electrogram delay recorded from left ventricular lead at implant predicts response to cardiac resynchronization therapy: Retrospective study with 1 year follow up. *BMC Cardiovasc Disord.* **12**: 34.
- 25 Saxon LA, Kerwin WF, Cahalan MK, Kalman JM, Olgin JE, Foster E *et al.* (1998). Acute Effects of Intraoperative Multisite Ventricular Pacing on Left Ventricular Function and Activation/Contraction Sequence in Patients with Depressed Ventricular Function. *Journal of Cardiovascular Electrophysiology.* **9**: 13–21.
- 26 Ypenburg C, Roes SD, Bleeker GB, Kaandorp TA, de Roos A, Schalij MJ *et al.* (2007a). Effect of total scar burden on contrast-enhanced magnetic resonance imaging on response to cardiac resynchronization therapy. *Am J Cardiol.* **99**: 657–660.
- 27 Ypenburg C, Schalij MJ, Bleeker GB, Steendijk P, Boersma E, Dibbets-Schneider P *et al.* (2007b). Impact of viability and scar tissue on response to cardiac resynchronization therapy in ischaemic heart failure patients. *Eur Heart J.* **28**: 33–41.
- 28 Ypenburg C, van Bommel RJ, Delgado V, Mollema SA, Bleeker GB, Boersma E *et al.* (2008a). Optimal left ventricular lead position predicts reverse remodeling and survival after cardiac resynchronization therapy. *J Am Coll Cardiol.* **52**: 1402–1409.
- 29 Ypenburg C, Van De Veire N, Westenberg JJ, Bleeker GB, Marsan NA, Henneman MM *et al.* (2008b). Noninvasive imaging in cardiac resynchronization therapy – Part 2: follow-up and optimization of settings. *Pacing Clin Electrophysiol.* **31**: 1628–1639.