

Leonardo da Vinci and Kethem – Kiveris vena

Antonín DOLEŽAL, Zita SKOŘEPOVÁ-HONZLOVÁ, Karel JELEN

Faculty of Physical Education and Sport, Department of Anatomy and Biomechanics, Charles University, Prague, Czech Republic

Correspondence to: Antonín Doležal
Faculty of physical education and sport, Charles University
Jose Martiho 31, Prague, Czech Republic.
TEL: +420 220172319; E-MAIL: dolezal@ftvs.cuni.cz

Submitted: 2012-09-10 Accepted: 2012-10-01 Published online: 2012-12-28

Key words: **Leonardo da Vinci; mamillar-uteral connection; Ketham**

Neuroendocrinol Lett 2012;33(8):732–735 PMID: 23391978 NEL331112A04 ©2012 Neuroendocrinology Letters • www.nel.edu

Abstract

In the drawing of coitus by Leonardo da Vinci are pictured the contemporary hypotheses regarding this act. The authors analyze the mamillar-uteral connection depicted by the artist and grow up to believe that this is a hypothetical kiveris vena, female vein described by Anatomist Master Nicolai Physicus from the Salerno School. The Hebrew roots were found in the name. The connection is described also by Mondino in *The Anathomia*. The same connection can be found in the picture of the pregnant woman in *Fasciculus Medicinæ* by Johannes De Ketham.

STUDY OF HISTORICAL MATERIALS

Compared to well-known contemporary reproductions the drawing is more sharply defined which for our purposes we consider preferable (Figure 1 – da Vinci, in Sumtibus Heroldi et Wahlstabii, 1830).

Coitus was repeatedly depicted by Greek and Roman artists (Varone 2001). Leonardo's drawing probably dates to the beginning of his studies around 1493 launched the project of embryological studies. There are three more detailed drawings of the topic (Morris 1986).

Leonardo da Vinci drew a cohabitation in a vertical position in the original indicated sagittal section led to perfection 380 years later by pioneer Biomechanist Christian Wilhelm Braune (1831–1892) on frozen sections (Braune 1875). A man is shown in profile, with no upper limbs, *a capite ad genua*, has long hair flowing to his chest. His face in the original Leonardo's drawing has enigmatic, neutral expression, which certainly does not say anything about the experience. The artist did not need to capture the accompanying emotions. In a copy from 1830, the expression is strenuous. The

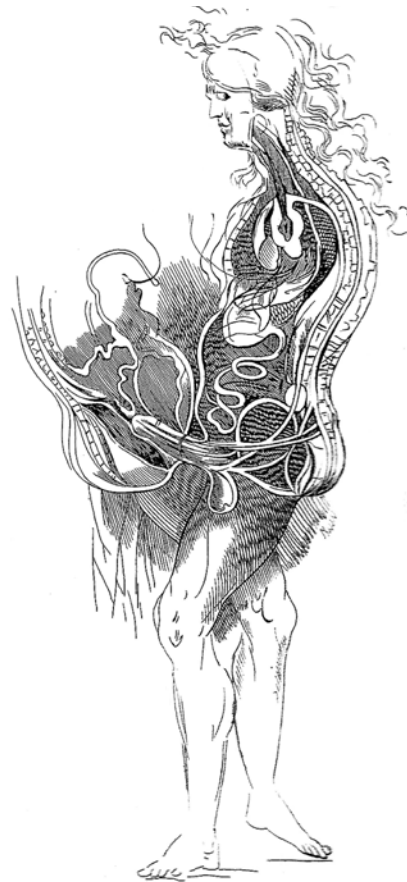


Fig. 1. Cohabitation (by Leonardo da Vinci).

man is turned with his left arm in front against the sagittal section which shows not the right leg, but erroneously the left leg.

The head section is visible along with schematically captured spine and vertebrae, brain, base of the skull and spinal canal, pharynx section. The heart can be also distinguished. The outgoing arteries, aorta, stomach, loose bowel loops, drawings do not meet anatomic topographic accuracy. The penis is erect. His radix – root passes to a bulky club-shaped formation in which it is difficult to decide what its meaning is. There was no indication of the prostate in the writing of the time. It could be the *bulbus* of the penis and surrounding *musculus bulbospongiosus*. The testicles are correctly displayed pulled cranially in the erection, which is also captured by Leonardo in the drawing from 1500–1515 “*Angelo Incarnato – The Angel in the Flesh*”. (Nicholl 2006). According to the theory of Hippocrates, the source of the semen is drawn in the brain and there are marked two, in fact nonexistent, outlets from the penis.

A woman is shown with her headless torso caudally from the breast. Her spine is schematically shown with no heart, no intestines and full bladder shown. Her uterus is depicted awkwardly. There was a contemporary idea that the uterus contains seven *cellulae* (Reichman 2010). Leonardo captured this belief in one sketch but not in this drawing (Morris 1986). In *Comentaria* (1521), Berengarius refuted this doctrine as irrelevant. “*Tamen est purum mendacium dicere quod matris habeat septem cellulas.*” (It is a sheer fabrication to say that her uterus has seven cells.) (Speert 1973).

We are getting to the part which we analyze more closely. From the breast depicted side-wise there is an apparent connection to the places where the uterus is shown in kind of waves. What did Leonardo have in mind drawing this connection? There is mamillar-uterine reflex, uterine contractions resulting from breast-feeding. In 1482, Leonardo depicts “*The Nursing Madonna and Child – Madonna Litta*”, in which the displayed torso is not breast-feeding. (Speert 1973). Does this connection capture a path of genital irritation from the breast? The drawing bears no erotic charge at all. No excitement figures there. According to medieval thought, this hypothetical vessel carried the suppressed menstrual blood to the mammary glands where it caused the enlargement of the breasts and the production of milk (Morris 1986).

Leonardo was familiar with the works of Aristotle, Galen, Mondini (Sandro & Baroni 1977). Educated doctors of that period had learned Arabic and Hebrew to understand the sources of local advanced medicine. In the 12th century in Salerno there was a famous medical school. Based on the *anatomium porci*, Arabists and Hebraists performed back-translation of original Greek writings. Shortly after the decree of Frederick II in 1241, as candidates for the practice of medicine had to study human anatomy, the practice of dissecting

human cadavers was begun at the medical school in the Bologna (Hintsche 1944).

A work *Anatomia Magistri* from Nicolai Physici (The Anatomy of Master Nicolaus), living around 1150–1200 AD, was translated into English by Corner (Corner 1927).

The *vena cava*, as we said before, divides into two branches as it leaves the liver, one of which goes upward, the other downward. The one which goes downward divides into numerous branches, some of which go to the stomach, others to the intestines, others to the kidneys, others to the legs, just as we said of the *vena chilis*. Through these veins nutritive blood and animal spirits are carried to nourish and comfort the members. All the foregoing veins are found in both sexes; but there is another vein which is found only in women, called **kiveris vena, that is, the female vein**. This vein begins in the liver, and as it leaves it divides into two branches, one of which goes upward, the other downward. The one which goes downward divides into two branches, one of which enters the right horn of the uterus, the other the left; and through these branches the menstrual blood is carried into the uterus, to be discharged later through the portal of the uterus. The branch which goes upward divides into two branches, one of which goes to the right breast, the other to the left. When the *os uteri* closes after conception, the menstrual blood is retained and part of it is transported by these veins to the breasts, where it is modified and transsubstantiated into the essence of the milk which provident ministering nature provides and prepares as nutriment for the foetus when it sees the light. The remainder of the menstrual blood is taken to nourish the foetus while it is in the maternal uterus.

We searched for the word “kiver” which has no Greek or Latin roots. This word is not mentioned in memoirs either of Fonahn (1922) or Hyrtl (1879). In the dictionary *The Brown-Driver Briggs Hebrew and English Lexicon*, we found several options and taking the grammar into account we noted by derivatives of the root *qaf-wav-resh* רוק, from which also come the words *maqor* רוקמ, i.e. “current” or “flow” and especially ***maqor dammeya*** רוקמד הימד, i.e. “Flow of menstrual blood” or “blood flow after birth” (Brown *et al.* 1996)

About this vessel is later rather inaccurately reported in 1316 by Mondino dei Liuzzi (1270–1326) in his essays *De anathomia vasorum spermaticorum in muliere* and *De anathomia mamillarum*, printed in Padua (Transcript and translation Monduzzi Editore, 1988).

... et propter eandem causam natura ordinavit venas quae veniunt a matrice ad eas tortuosas, ut ibi dicit Galienus procedere tortuose ad hoc, ut sanquis continue subtilietur et bene digeratur ... Et ex hiis apparet colligantia. earum, quae ipsae colligatae sunt cum corde et epate per venam descendentem, a qua iuxta furculam ramificantur duo rami qui descendunt supra dorsum et inter costas tendunt ad nanillas. Colligantur etiam cum

matrice mediantibus venisque ascendent a matrice ad mamillas, de quibus dictum est supra.

In translation: ... and thus nature arranged it so tortuous veins leading from the uterus to them (breasts). As Galen says, they are tortuous for the blood to be constantly refined and well dispatched... Their connection is obvious from it, that they are themselves connected with the heart and liver through the “*venam descendentem*” from which near the fork (*furcula*) are separated two branches, which descend over the back and between ribs go towards breasts. They are also linked to the uterus through *venes mediantes* that protrude from the uterus to the breasts called shoa.

During our study of contemporary sources, we came upon the first medical book including illustrations, *Fasciculus medicinae*, printed in Latin in 1491, hence earlier than the drawing of Leonardo da Vinci was made. It was written by the Swabian Doctor Johannes de Ketham-Johannes von Kirchheim, working in the 1460s. The authors have at their disposal a copy of the book translated into Italian *Fascicolo de Medicina* from 1494 (Ketham 1494; Speert 1973). In this publication is a drawing of a pregnant woman sitting *en face* in the delivery chair (Figure 2).

The uterus is displayed correctly pear-shaped. From the right breast there is a fat link to the left side of genitalia. To the image is attached an old Italian text, which we publish with our translation, about the depicted mamillar-uterine connection of which it specifies nothing. It only illuminates the contemporary medical environment.

Sono alcune cose da notare e alcuni segni de la coceptione dela donna el primo segno e quello che se cognosce per la comunione de lo homo i de la dona. Imperoche se la donna doppo el coniongimero sentira freddo o dolor de reni e segno de conceptione. I se el color dela faccia fuor delusato se viene ad mutare e segno de coceptione. Et se desidera alcun cibo insirato come terra o carbom e segno de coceptione. Et se tu vorrai sapere se e maschio o femina quello che e coceptuto: sel color del volto e rossa i el ventre se gionfia de la parte dextra in forma rotonda i el lacte esce delle poppe spesso i ben corto i digestito i se ponendolo sopra una casa pulita nono se dispartisce ma stara insieme allora sara masculo.

There are some interesting signs of woman pregnancy and the first one is that a woman has connected herself with a man. So if a woman feels cold or pain in the kidneys after this connection, it is a sign of conception. Also if her face often changes color, it is a sign of conception. It is also a sign of pregnancy if she often wishes often bland food such as charcoal or clay. If we are interested in whether the fetus was conceived as male or female: if a woman has a red face and belly bulging to the right and when there is often milk leaking from her breast in short intervals and this milk,

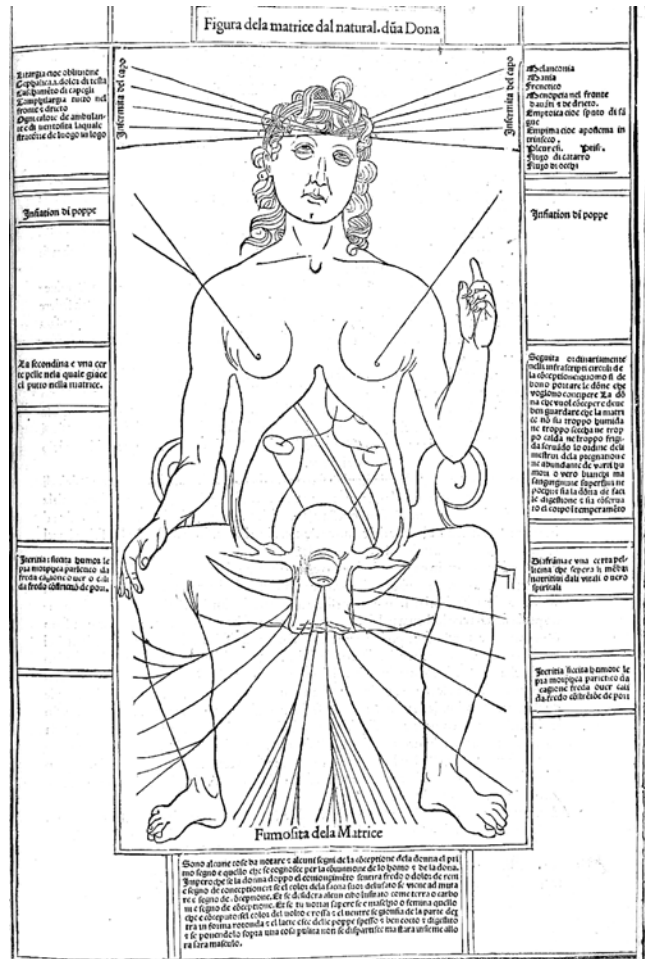


Fig. 2. Pregnant (Ketham 1494).

when it gets on a clean surface, does not spread but remains together, it will be a boy.

CONCLUSION

Leonardo's drawing of coitus as well as a drawing from Ketham is not based on actual anatomical studies of male and female, but on ancient and medieval hypotheses. *Kiveris vena* is just one of the then medical myths. In the writings of Galen *De usu partium* and in Arabic and Hebrew medicine emphasis was placed on teleology – the effectiveness of the organs. Science at that time did not have the apparatus necessary to explain the functions that were only originating in the emerging natural technical sciences. The struggle to replace this deficiency with synthetic philosophy obviously failed.

ACKNOWLEDGEMENT

This project is supported by grants GACR 407/10/1624 and PRVOUK 38.

REFERENCES

- 1 Braune CW (1877). *Topographisch-anatomischer Atlas, nach Durchschnitten an gefrorenen Kadavern*. Leipzig: Veit 1875. 218 p. Translated into English by Bellamy, E. as: *An atlas of topographical anatomy after plane selections of frozen bodies*. London: J. & A. Churchill.
- 2 Brown F, Driver Sr, Briggs CA (2007). *The Brown-Driver-Briggs Hebrew and English Lexicon*. Massachusetts: Hendrickson Publishers, 1185p.
- 3 Corner GW (1977). *Anatomical Text of the Earlier Middle Ages: a study in the transmission of culture, with a revised Latin text of Anatomia Cophonis and translations of four texts*. Washington: Carnegie Institution of Washington. Reprint New York: AMS Press, 1977. 112p.
- 4 Fonahn AM (1922, 2010). *Arabic and Latin Anatomical Terminology Chiefly from the Middle Ages*. Kristiania: J. Dybwad Publication, 1922. Reprint Memphis: General Books LLC, 2010. 124 p. ISBN 1151897779
- 5 Hintsche E (1944). Anatomische Forschungen im Mittelalterischen Abendland. *Ciba Zeitschrift*. **96**: 3426–3438.
- 6 Hyrtl J (1966). *Das arabische und hebräische in der Anatomie*. Wien: W. Braumüller, 1879. 376 p. Reprint Sändig, 1966. 311 p.
- 7 Ketham J (1494). de. *Fasiculo de Medicina*. Venice: Zuane & Gregorio di Gregorii, on line: <http://archive.nlm.nih.gov/proj/ttp/flash/ketham/ketham.html>
- 8 Leonardo Vinci da (1830). *Tabula anatomica Leonardo da Vinci summi quondam pictoris e bibliotheca Augustissimi Magnae Britanniae Hannoveraeque Regis depromta, venerem obversam e legibus naturae hominibus solam convenire, Ostendens*. Lunaeburgi: Sumtibus Heroldi et Wahlstabii.
- 9 Liuzzi Mondino dei (1981). *Anothomia*. Manuscript 1316. Transcript and translation Bologna: Monduzzi Editore, On-line: <http://137.204.24.205/Mondino/textus.html>
- 10 Morris AG (1986). *History of Medicine: On the Sexual Intercourse Drawings of Leonardo da Vinci*. The South African Medical Journal (SAMJ) 69(4): 510–513.
- 11 Nicholl Ch, Bischoff M (2006). *Leonardo da Vinci*. Frankfurt: Fischer, 751p.
- 12 Pioreschi P (1996). *A History of Medicine: Medieval Medicine*. Omaha, NE: Horatius Press, 804p.
- 13 Reichman E (2010). Anatomy and the Doctrine of the Seven-chamber Uterus in Rabbinic Literature. *Hakirah, the Flatbush Journal of Jewish Law and Thought*. **10**(winter): 245–265.
- 14 Sandro P & Baroni C (1977). *Leonardo da Vinci. Das Lebensbild Eines Genies*. Wiesbaden, Berlin: Emil Vollmer Verlag, 1977. 532 p.
- 15 Speert H (1973). *Iconographia Gyniatrix*. Philadelphia: FA Davis. 540 p.
- 16 Varone A (2001). *Eroticism in Pompeii*. Los Angeles: J. Paul Getty Museum 2001. 115 p.
- 17 Vasari G (2005). *Le vite de piu eccellenti architetti, pittori et scultori italiani da cimabue insino a tempi nostri*. Edizione per i tipi di Lorenzo Torrentino, Firenze 1550. Reprint Giulio Einaudi Editore, Torino: Einaudi tascabili. Classici 72, 1037 p.