

Assessment of Bilateral Inferior Petrosal Sinus Sampling in the diagnosis and surgical treatment of the ACTH-dependent Cushing's syndrome: A comparison with other tests

Xiuhua SHI¹, Qingfang SUN¹, Liuguan BIAN¹, Weiguo ZHAO¹,
Jiankang SHEN¹, Weiqing WANG², Guang NING²

¹ Department of Neurosurgery, Ruijin Hospital, Shanghai JiaoTong University School of Medicine, Shanghai, China

² Department of Endocrine and Metabolism, Ruijin Hospital, Shanghai JiaoTong University School of Medicine, Shanghai, China

Correspondence to: Qingfang Sun, MD., PhD; Liuguan Bian, MD., PhD.
Department of Neurosurgery,
Ruijin Hospital, Shanghai Jiao Tong University School of Medicine
197, Rui Jin Er Road, Shanghai 200025, China.
TEL: +86-21-64370045-666091; FAX: +86-21-64333548;
E-MAIL: rjns123@yahoo.com.cn; shixiuhua1027@gmail.com

Submitted: 2011-09-07 *Accepted:* 2011-09-19 *Published online:* 2012-01-15

Key words: **bilateral inferior petrosal sinus sampling; ACTH-dependent Cushing's syndrome; diagnosis; transsphenoidal surgery**

Neuroendocrinol Lett 2011; **32**(6):865–873 PMID: 22286783 NEL320611A17 ©2011 Neuroendocrinology Letters • www.nel.edu

Abstract

BACKGROUND: Bilateral inferior petrosal sinus sampling (BIPSS), currently, is the gold standard test for the differential diagnosis of Cushing's syndrome (CS), but few data are available on the efficacy and accuracy of BIPSS in the qualitative diagnosis of ACTH-dependent CS and lateralization of Cushing's disease (CD); especially, the evaluation of BIPSS in all CD patients with transsphenoidal surgery (TSS). As a result, we investigated whether such invasive test compared other non-invasive tests may affect the efficacy and accuracy of diagnosis and TSS treatment in ACTH-dependent CS. **OBJECTIVE:** We investigated the efficacy and lateralized accuracy of diagnostic and therapeutic of BIPSS in ACTH-dependent CS. **SETTINGS:** A retrospective analysis was conducted at a single care center in Ruijin Hospital, Shanghai City. **PARTICIPANTS:** CD was confirmed by histopathology in one hundred and nineteen patients, include sixty-four patients with BIPSS procedure; and ectopic ACTH syndrome (EAS) also was histological confirmed in five patients. **MAIN INTERVENTIONS AND OUTCOMES:** Sixty-nine patients were all administrated with BIPSS test. Additionally, other noninvasive tests included endocrine examinations, low and high dose dexamethasone suppression test (LDDST and HDDST); imagine examinations include magnetic resonance imaging (MRI) and positron emission tomography and computerized tomography (PET-CT). Gradients of inferior petrosal sinus (IPS) to peripheral (IPS/P) ACTH were calculated before and after BIPSS procedure completed five minutes. **RESULTS:** In patients with proven pituitary cases, stringent response criteria in MRI and HDDST testing were fully by 51.6% and 60.3% respectively. While BIPSS, gave direct evidence of CD in 90.6% of these cases. The sensitivity for a basal IPS/P gradient greater than 2 was 89.1%, with 100% specificity and a diagnostic

accuracy of 87.5%. A subgroup of 14 patients (all were CD) had contradictory responses to routine test with HDDST; while the sensitivity, specificity and accuracy of BIPSS were 100% respectively. Compared with the MRI and DST, we accepted Receiver Operating Characteristic (ROC) curve analysis showed that BIPSS performance is the best efficacy diagnosis tool in CS. In total, 57 of 64 patients with CD had an IPS/P gradient greater than 2, resulting in the sensitivity, specificity and diagnostic accuracy are 90.5%, 100%, 95.2% respectively. Additionally, the accuracy value of BIPSS in indicating dominant side should also be stressed in adenoma lateralization of CD. Finally, BIPSS test contributed most in the remission efficacy of TSS; then remission rate of underwent BIPSS group is 92.2% compared to the rate of 80% in without BIPSS group ($p < 0.01$). Compared with other noninvasive tests, turn out the highest accuracy rate in remission. **CONCLUSIONS:** The application of BIPSS is associated with efficacy and accuracy of ACTH-dependent CS and lateralization of CD, what's more, all above, we can conclude that BIPSS is associated with the surgical therapy in CD patients. Therefore, BIPSS dedicate to the diagnosis, treatment and intraoperation administration of ACTH-dependent CS.

Abbreviations

BIPSS	- Bilateral inferior petrosal sinus sampling
ACTH	- Adrenocorticotrophic Hormone
CS	- Cushing's syndrome
CD	- Cushing's disease
TSS	- transsphenoidal surgery
EAS	- ectopic ACTH syndrome
LDDST	- low dose dexamethasone suppression test
HDDST	- high dose dexamethasone suppression test
MRI	- magnetic resonance imaging
PET-CT	- positron emission tomography and computerized tomography
IPS	- inferior petrosal sinus
IPS/P	- to peripheral
ROC	- Receiver Operating Characteristic
C/P	- Central/peripheral
DST	- dexamethasone suppression test
CRH	- corticotrophin releasing hormone
R/L	- right/left
BICSS	- Bilateral inferior cavernous sinus sampling
CT	- computed tomography

INTRODUCTION

Cushing's syndrome is a clinical condition that long-standing exposure to elevated levels of cortisol, results in increased mortality and impaired health. In a recent meta analysis, Ezzat *et al.* found an overall prevalence of pituitary adenomas of 16.7% (14.4% in autopsy studies and 22.5% in imaging studies) (Ezzat *et al.* 2004). Of the cases in which the cause is ACTH-dependent, approximately about 70% are due to a pituitary adenoma (CD); in the remaining cases, the hypercortisolism is secondary to ectopic ACTH secretion about 10%. When an obvious neoplastic source of ACTH hypersecretion is absent, CD accounts for about 90–95% (Newell-Price *et*

al. 2006). Obviously distinguish between pituitary and ectopic ACTH secretion syndrome is of great necessity, almost all the researches maintained the most direct method is BIPSS (Orth 1995).

Traditionally, differential diagnosis has relied on dynamic tests, especially the HDDST, with its sensitivity of only 80% and some question of usefulness in the differential diagnosis of CS (Ezzat *et al.* 2004; Orth 1995; Isidori *et al.* 2006). MRI, in addition, has relatively poor sensitivity and specificity for identifying a pituitary mass lesion. MRI performed in virtually all patients with suspected CD, while only 50% of pituitary adenomas were detected in the frequent occurrence of incidental pituitary adenomas (Tsagarakis *et al.* 2007). BIPSS has been proven to be a highly accurate investigative tool in the differential diagnosis of ACTH-dependent CS. Based on it, a peak central to peripheral ACTH ratio of 2:1 or greater most reliable identifies a pituitary source of CD; intercavernous gradient of ACTH greater than 1.4, was indicative of adenoma lateralization (Lefournier *et al.* 2003), demonstrated a high sensitivity and specificity up to 100% (Wiggam *et al.* 2000). Nevertheless, with the exception of Lefournier's study (McCance *et al.* 1989), which quoted the accuracy approaching 71%; while in subsequent series a false-negative rate of 4–15% has been reported (Wiggam *et al.* 2000).

From a therapeutic point of view, distinction in the ACTH-dependant CS is essential so that patients can be confidently referred for the treatment of choice, include pituitary microsurgery, and patients with EAS can be spared the risks of BIPSS (Bonelli *et al.* 2000). BIPSS is of great help to assist the neurosurgeon patients with CD who show equivocal results at dynamic testing and/or pituitary MRI, but its role in localizing the indiscernible or small micro-adenoma in the pituitaries of these patients is remained to further discussed. Given these difficulties, we sought to identify factors of diagnostic efficacy and lateralized accuracy of BIPSS in CS would be reliable. We hypothesized both the efficacy and accuracy might influence the value of the CS provided by BIPSS. We reported our experience with sixty-nine consecutive cases of ACTH-dependent CS, whose investigation included LDDST, HDDST, and MRI; also BIPSS while a subgroup of fifty-five CD without it. Besides, the EAS group also underwent PET-CT imaging. The usefulness of the various diagnostic tests is examined along with the implications of applying the new stringent diagnostic criteria.

PATIENTS AND METHODS

Patient population

We reviewed the case records of 69 consecutive patients (51 women and 18 men; mean age, 37.1 yr; range, 15–63 yr) with ACTH-dependent Cushing's syndrome, between 2003 and 2011. BIPSS were performed in all patients by the same team of skilled neuroradiologists (Zhang *et al.*) in Ruijin Hospital. The procedure was

technically successful with the overall rate almost 100%. Central/peripheral (C/P) ACTH gradient was almost consistent with pituitary CD and went on to evaluation and treatment of ectopic ACTH syndrome. All patients accepted physical examination, biochemical tests, endocrine tests included plasma cortisol, 24-h urinary free cortisol, ACTH levels, a LDDST (2 mg-dose, 0.5 mg every 6 h for 2 d, p.o) and HDDST (8 mg-dose, 2 mg every 6 h for 2 d, p.o) dexamethasone suppression test (DST). Positive response in HDDST or LDDST, present with a decrease of more than 50% suppression of serum cortisol and 24-h urinary free cortisol, and /or ACTH more than 50% over the baseline values. Imaging was performed in all patients with pituitary MRI both before and after the injection of gadolinium. What's more, suspected ectopic ACTH syndrome patients received the PET-CT.

In this series, 64 patients had pituitary-dependent Cushing's disease established on the basis of histological confirmation or apparent cure or significantly biochemical improvement after transsphenoidal surgery of pituitary (TSS). Finally, 5 cases of EAS were pathological combined with PET-CT diagnosed as mediastinal carcinoid, tubulovillous adenocarcinoma and pancreatic cancer. Our main analysis is based on 119 cases of pathology identified as CD, included 65 with BIPSS while 54 without the examination. All CD patients underwent the TSS with the same two doctors.

Data collection

All available clinical, laboratory, radiographic, and pathological data at preoperative diagnosis as well as in postsurgical follow-up were collected from the cooperation with several departments in our center. We then

attempted to contact all patients for a follow-up, using multiple search techniques if needed.

The study was approved by the ethical committee of our institution, and informed consent was obtained from all patients.

BIPSS performance

All 69 patients were referred for BIPSS before surgery, with/without a clear pituitary lesion on MRI (either a negative or an equivocal scan) and/or patients with biochemical testing (inadequate suppression on DST) or clinical presentations in consistent with CS. This routine procedure was performed as previously reports described (Kaskarelis *et al.* 2006).

BIPSS was performed with a plate DSA system (Innova, General Electric Medical System, Milwaukee, WI, USA), insert with the guide wire, after systemic anticoagulation with heparin and sedation, the needle and wire are exchanged for a venous sheath and repeat it on the opposite side. After catheter placement, position was verified in each case by injection of contrast agent (Crapo 1979). Under the fluoroscopically-guided catheterization was performed, with 5Fr and 4Fr (RF*GA35153 m, 0.035", TERUMO Co, Tokyo, Japan) inserted percutaneously into the right and left inferior petrosal sinus respectively (shown in Figure 1). 1~2 ml contrast material was softly injected by hand to obtain digital subtraction venograms of both petrosal and cavernous sinuses to assess the precise location of the catheter tips. All patients both petrosal sinuses were successfully catheterized, ACTH level was measured by an immunoradiometric method (CIS bio international, Gif/Yvette, France; with intra- and interassay CVs < 14% and < 20%, respectively) in 2 milliliter blood obtained

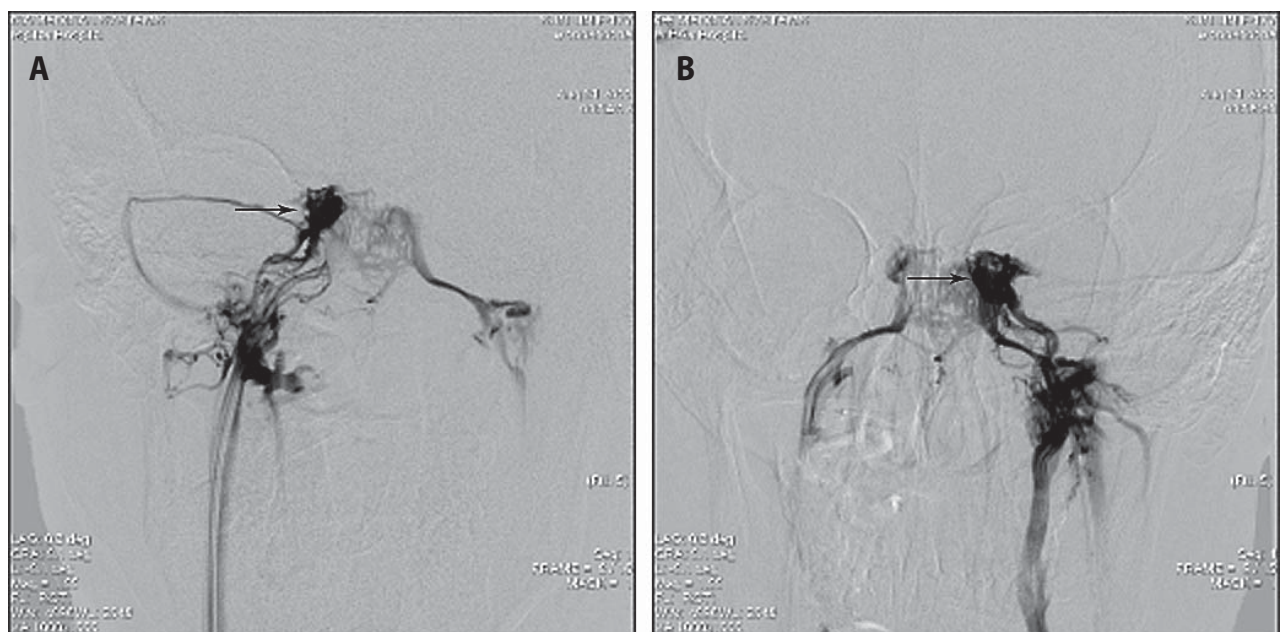

Fig. 1. Catheterization with 5Fr and 4Fr (RF*GA35153 m, 0.035", TERUMO Co, Tokyo, Japan). A - Right, B - Left.

from each petrosal sinus and from a peripheral vein, 5 minutes later blood collection repeatedly. Samples for ACTH measurements were immediately placed into EDTA-containing (sodium ethylenediamine tetraacetic acid, EDTA) tubes and placed kept in ice until the completion of the procedure and then were spun at 4°C, and the plasma was separated and stored at 20°C until assay. The highest ratio of ACTH values in IPS samples to the level simultaneously measured from the peripheral vein sample was used as an indicator of the diagnosis of CD. We consistent with previous reports, an IPS/P ratio of is more than 2, was taken as suggestive of CD (Kennedy *et al.* 1984). Based on our procedure, minor side effects such as transient swelling or pain, projectile vomiting at the sites of catheterization, but no serious complications after the BIPSS procedure were recorded in this series, except 1 case contrast agent entre to the subarachnoid cavity.

In our center, what is worth mentioning, the use of corticotrophin releasing hormone (CRH) stimulation did not performed in any patients. For one thing, recently the source of CRH is limited in China; For another thing, patients maybe hardly afford to the high expense of CRH. Particularly, the reason high expense of the BIPSS procedure added on the operation fee lead to that the BIPSS procedure with CRH stimulation cannot completely be performed in our center.

Endocrine hormone evaluation

Dexamethasone tests were carried out in 69 patients, included LDDST and HDDST. Serum cortisol was measured at 0800 h on day1, just before the first 0.5-mg dose, and then at 0800 h daily until completion of the test (days 2–5). The percent suppression of serum cortisol was calculated as follows: %suppression= (basal value – final value) / basal value*100. Our normal practice is to take the day 1 value as basal. In our series, 38 patients unsuppressed in LDDST accompanied with HDDST suppressed, confirmed diagnosis of CD; and 5 cases were both unsuppressed in DST indicated as EAS. Undetectable serum cortisol after preliminary LDDST was found in 2 patients. Therefore, the HDDST was deemed unnecessary (Both of these 2 patients had evidence of cyclical hypercortisolism) (Tritos *et al.* 2011). In this analysis, these 2 patients have been considered fully responsive to HDDST. Serum cortisol was estimated by direct radiological immunometric assays (RIA, DiaSorin, Clinical Assays Gamma Coat Cortisol 125I RIA Kit) as previously described (Jehle *et al.* 2008).

MRI and PET-CT imaging evaluation

Of all 69 patients performed MRI of the pituitary gland before the TSS. In general, MRI images included sagittal and coronal T1-weighted, coronal T2-weighted MRI images in thin sections (2 mm, magnet strength with 1.5 Tesla), and followed by a dynamic coronal T1 sequence beginning simultaneously with the contrast injection Gd-DTPA (Bayer Schering Pharma AG,

Berlin, Germany). Pituitary MRI was reviewed independently by different neuroradiologists as well as by the pituitary neurosurgeon (Zhang H). Classification of the pituitary lesion as an adenoma, and definition as positive, equivocal or negative was also made by the same neurosurgeon in conjunction with at least one neuroradiologist.

Suspected EAS cases had accepted the PET-CT, all were indicated as of ectopic neoplasia include mediastina carcinoid (three cases), tubulovillous adenocarcinoma and pancreatic carcinoma.

Treatment

The treatment of CD is the surgical removal of TSS performed by two experienced surgeons. However, some patients underwent bilateral adrenalectomy. For the remission criterion of CD varied between institutions and studies, combined with latest literatures, our center defined as the laboratory tests and end points include very low early-morning serum levels of cortisol or ACTH, low 24h urine free cortisol levels, and normal cortisol suppression in response to dexamethasone administration (either 1 mg or 2 mg dexamethasone), measured in the first 2 weeks after surgery (Testa *et al.* 2007). While we adopted the standard level of blood cortisol is lower than 5 µg/dl.

Statistical analysis

Statistical analysis was carried out using SPSS 17.0. The results of continuous data are expressed as mean±SD, performed with the *t* test. Then discontinuous data results were performed with the Chi-square test. ROC curve was constructed to examine the best diagnostic efficacy performance of BIPSS, MRI and DST, with their ability to discriminate between patients with CD and EAS. Sensitivity against 100% specificity of data was plotted at each level, and the area under the curve was computed by the nonparametric Wilcoxon's test statistic. Areas under the curve represent the probability of efficacy in identifying CD and EAS patients. Regarding calculation of the diagnostic accuracy of MRI, findings that appeared negative or equivocal were classified as negative. Between all CD patients of BIPSS underwent and not underwent group, Chi-square test was computed. The level of significance was set at 0.05 in all statistical tests.

RESULTS

Results of pituitary histology, PET-CT, and the other investigations in the 69 patients with confirmed diagnosis are summarized (shown in Table 1).

BIPSS performance characteristics

Using a published cut-off for BIPSS, we conclude that a central /peripheral ratio of 2.0 accurately distinguished Cushing's disease from the ectopic ACTH syndrome in all CS patients except 8 cases (shown in Figure 2).

Patients with CD showed ratio more than 2 while 7 patients showed a basal gradient less than 2, however, they finally confirmed as CD; in contrast, 1 case showed a basal gradient more than 2, 1 case data is missing, but the progress noted the basal ratio low than 2; finally, all 5 cases confirmed as EAS.

To determine an optimal examination for the BIPSS compared to the traditional MRI and DST examinations. We computed with the ROC curve analysis (shown in Figure 3), then the area under the curve (AUC) for the BIPSS was 0.952 ($p=0.003$, 95% CI=0.900–1.005), however, the area of MRI and DST test were 0.754 ($p=0.09$, 95% CI=0.591–0.917) and 0.852 ($p=0.044$, 95% CI=0.663–0.940) respectively. As a result, BIPSS indicated an excellent test performance. Using a cut off value for the basal IPS/P ratio of 2 or greater, both maximal sensitivity (90.6%) and specificity (100%) for the distinction between CD and EAS were achieved. In addition, the accuracy sensitivity of different tests involved in the ACTH-dependent CS diagnosis is also different (shown in Table 2)

All the CD treated with TSS, when comes to the remission rate, finally we found the BIPSS test contributed most to the surgical remission between different tests (shown in Table 3).

Initial R/L ratios \leq 1.4 revealed the evidence of lateralization gradient in pituitary adenoma. Characteristics of the MRI findings, the surgical adenoma location and the BIPSS lateralization accuracy in CD diagnosis are essential to the TSS treatment of pituitary disease (shown in Table 4); especially, based on the accurate lateralization in operation, the accuracy of BIPSS was higher than MRI (shown in Table 5). In our research, consistent with R/L ratio more than 2 were proven in 57 cases; reversal of lateralizing gradient were found in 7 patients, which were submitted to TSS with surgical histopathology of a pituitary ACTH-producing tumor. No lateralization (elevated levels in both sides) was detected during BIPSS in 10 patients, maybe due to a lesion with in the central part of the pituitary. ACTH level of C/P gradient was not observed in 1 case of 64 CD; while in EAS 1 reversal C/P gradient out of 5 were finally surgically proved to have ectopic ACTH-producing syndrome. It is worth to note the inconclusive surgery description effected the tumor location definition.

DISCUSSION

It is controversial that the necessity of venous sinus sampling such as BIPSS in patients with positive endocrinological tests for CD and with lesions detected in MRI. The role of BIPSS in the work-up of patients with ACTH-dependent CS varies between centers. Most researchers maintain that BIPSS should be done in all patients with negative or inconclusive pituitary imaging studies and those with discordant biochemical and imaging results; additionally, selective use of BIPSS

Tab. 1. Characteristics of all the CS patients in clinical information and laboratory tests.

	CD N=64	EAS N=5
Sex (F/M)	16/48	2/3
Age (yr)	36.05±11.58	50.6±11.01
Follow-up (m)	29.13±16.26	32.50±45.79
0800 h cortisol	33.01±28.64	40.23±26.43
Midnight cortisol	21.50±6.93	35.83±23.17
Urine cortisol/24h	505.3±296.49	734.25±225.86
Serum ACTH level (pg/ml)	111.35±75.28	277.01±265.5
Pathology positive (pituitary adenoma)	60/64 (60, adenoma; 2, hyperplasia; 2, normal pituitary)	EAS (mediastina carcinoid, pancreatic carcinoid, tubulovillous adenoma)
Sellar MRI image positive	33 (33/64)	1 (1/5)
PET-CT	None	All with ectopic tumor

N: number, F: female, M: male, yr: year, m: month, h: hour

Tab. 2. the diagnosis accuracy of different tests involved in the ACTH-dependent CS.

Tests	Patients	Criterion	Sensitivity	Sensitivity of diagnosis in EAS
MRI	33/69	Reveal adenoma, micro- or macro-adenoma	47.8%	1/5 (pituitary MRI positive)
DST	38/68	LDDST unsuppressed and HDDST suppressed more than 50%;	55.9%	5/5 (both DST were unsuppressed)
BIPSS	58/68	C/P > 2.0	85.3%	4/5 (except 1 with C/P > 2.0)

Tab. 3. the remission efficacy of different tests involved in TSS treatment of ACTH-dependent CS.

Tests	Positive	Remission	Efficacy ratio	p-value
MRI	33/69	31/69	44.9%	0.542
DST	38/68	35/68	50.7%	0.613
BIPSS	58/68	53/68	76.8%	0.440

has been recommended, because the procedure is invasive, and although permanent neurological injury is rare (Kaltsas *et al.* 1999). Rarely, some centers performed BIPSS only if biochemical testing is inconclusive, regardless of imaging study results (Meier & Biller 1997). Other centers, however, performed in all patients with ACTH-dependent hypercortisolism (Machado *et al.* 2007) or all those with pituitary tumors less than 8mm in size (Oldfield *et al.* 1991). In our center, BIPSS

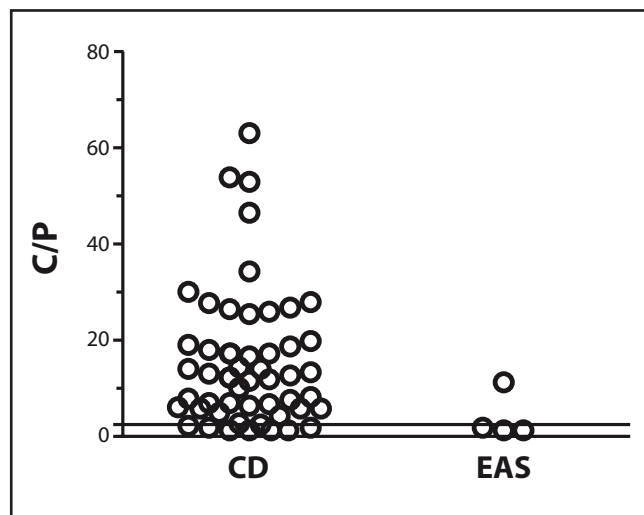


Fig. 2. Basal IPS/P ratios in ASTH-dependent CS.

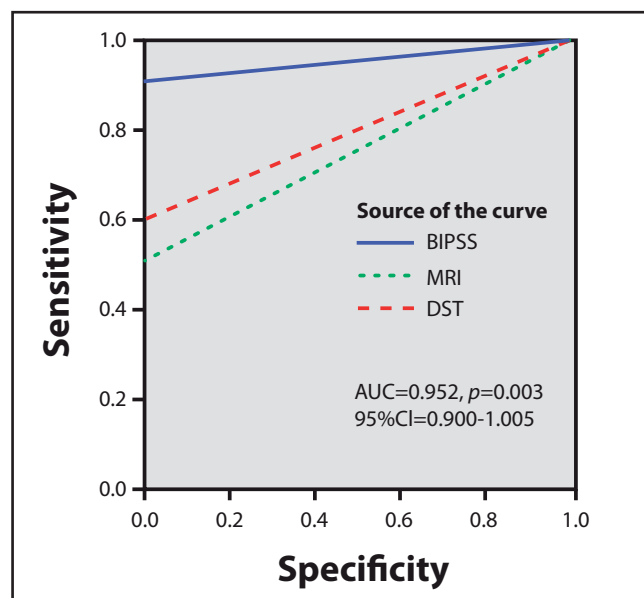


Fig. 3. ROC curve.

was carried out from 2009, especially BIPSS performed in patients without a positive adenoma on MRI or inconsistent biochemical testing for CD. BIPSS is a very valuable tool in ACTH-dependent CS, the diagnostic accuracy of this procedure is now known to be average at 94% as aforementioned series reported (Findling *et al.* 1981). We are not, therefore, in a position to comment upon the specificity of the diagnostic tests used. Our analysis rather focuses upon the sensitivities of the various tests, with possible implications for their relative roles, when the more stringent criteria are applied to both the HDDST and the MRI examination. Recently, both false-negative and false-positive in BIPSS procedures diagnosis of CS have been reported in many researches. In our series, the accuracy of BIPSS is 90.6% and 100% for diagnosis the CD and EAS respectively. An IPS/P gradient above 2 was obtained in 57 of the 64

Tab. 4. Results of different diagnostic tests in the lateralization of the adenoma.

	CD (n=64)	EAS (n=5)
MRI of pituitary gland	64	5
Micro-adenoma	31	1/5
Macro-adenoma	2	0/5
Equivocal	18	0/5
Negative	13	4/5
IPS/P ratio	16.83±14.77	1.25±0.38
IPS/P ratio>2	57/64	1/5
R/L>1.4	54/64	0/5
Surgical location (definite location)	61/64	Ectopic ACTH syndrome

Tab. 5. the accuracy of lateralization with MRI and BIPSS tests for predicting the tumor location in ACTH-dependent CS (n=64).

Items	Location	Accuracy ratio
Intraoperative adenoma lateralization	L:21 R:31 B:10 U:2	96.9% (62/64)
MRI test indicative in tumor lateralization	33	51.6% (33/64)
MRI test result consistent to the intraoperative lateralization	38	59.4% (38/64)
BIPSS test indicative in tumor lateralization	38	55.9% (38/64)
BIPSS test result consistent to the intraoperative lateralization	44	68.8% (44/64)

L: left, R: right, B: both sides, U: unknown

patients with Cushing's disease (7 false-negative result). This is in keeping with the false negative rate in a previous series of the undiagnosed even after biochemical testing and IPSS (Bonelli *et al.* 2000). IPS/P gradient less than 2 was obtained in 4 cases with EAS. Nevertheless, it is required that further study with a much greater number of patients with EAS should be obtain from patients with regard to the specificity during BIPSS and to give definitive recommendations regarding changes in the well-established ratios. It is recognized, however, that even in the most experienced hands, bilateral catheterization is not always possible (Blunt *et al.* 1990). For the need for sampling higher than that in the jugular bulb has long been recognized, as blood from the jugular bulb is admixed with blood from different areas of the brain (Alzahrani *et al.* 2009), so results from unilat-

eral sampling are only of diagnostic value if an elevated petrosal/peripheral ratio is found.

Traditionally, the HDDST has retained a central role in the differential diagnosis of Cushing's syndrome for many years (Orth 1995), and commonly greater than 50% suppression of urinary 17-hydroxysteroid after HDDST for 48h has been taken as evidence of pituitary disease (Tritos *et al.* 2011). Given limited evidence that the suppressibility of serum cortisol in response to HDDT may be slightly less than that of urinary free cortisol, later criterion has subsequently been extended to urinary free cortisol and serum cortisol greater than 50% suppression. CD was unsuppressed in LDDST and suppressed in HDDST, while it is clear from previous reports that patients with EAS may achieve greater than 50% suppression of serum cortisol after HDDT (Mamelak *et al.* 1996). In our research, the efficacy and accuracy of DST in diagnosis of CS, especially in Cushing's disease are 55.9%, and the sensitivity is about 80.2%. The ROC area which indicate less important role compared with the BIPSS in the diagnosis of CS. One approach might be to employ a combination of biochemical tests using stringent diagnostic criteria to achieve the specificity of 100%, if BIPSS is to be avoided. Then, a positive response to HDDST cannot exclude the possibility of ectopic ACTH secretion and obviate the need for BIPSS.

Although be various in centers, including our own. Some hold BIPSS routinely in the differential diagnosis of ACTH-dependent Cushing's syndrome; others advocate a more selective use of BIPSS, based on the uncertain results of biochemical and radiological investigations.

In addition, traditional MRI of pituitary should be performed in all patients with suspected ACTH-dependent CS, but this may reveal pituitary adenoma in no more than 36–78% of cases in adult series (Meier & Biller 1997). In our center, all suspected patients underwent the pituitary MRI examination, particularly contrast enhancement is used. Tsagarakis *et al.* reported that the MRI diagnostic accuracy is only 49% (Wiggam *et al.* 2000). In our results, the sensitivity of MRI is 50.8%, and the ROC under area is 0.754, which also less than BIPSS and DST areas. MRI positive indicated with the pituitary adenoma was obtained in 33 of the 64 patients, while 1 of 5 EAS patients was indicated pituitary micro-adenoma. MRI present with negative and equivocal may show as pituitary large or complete empty sellar syndrome.

In our center, in order to detect the primary disease, we had administration the suspected EAS cases with the PET-CT. PET-CT is positive in around about 60% of the cases of CD. Although the majority of cases with positive PET-CT had positive MRI, PET-CT may detect some cases with negative MRI and thus provides important diagnostic information. If these findings are confirmed in larger studies, PET-CT might become an

important diagnostic technique, especially when the more invasive and technically demanding procedure of BIPSS is not available or inconclusive (Gazioglu *et al.* 2008). As a result, all EAS patients had found ectopic focuses, including mediastina carcinoid (3 cases), tubulovillous adenocarcinoma (1 case), pancreatic cancer (1 case).

Although being effective in differentiating central and ectopic Cushing syndrome, BIPSS is not considered reliable in determining the abnormal side of the pituitary by some authors (Booth *et al.* 1998). In the present study, Bilateral inferior cavernous sinus sampling (BICSS) was able to correctly lateralize the lesion in 80% of cases more than BIPSS (Findling *et al.* 1991). Compared with BICSS, BIPSS was reported to predict the intra-pituitary tumor site with only an average of 78% diagnostic accuracy (Colao *et al.* 2001). In 40 patients studied by Teramoto *et al.* showed the results for lateralization of an ACTH-secreting adenoma were 91% accurate with BCSS, compared with 68% for BIPSS without CRH stimulation (Teramoto *et al.* 1998). Lefournier *et al.* reported the lateralization ratio was significantly more accurate in predicting a lateral tumor (76% of the patients with a lateralization ACTH ratio >1.4 had a homolateral tumor) than in predicting a midline tumor (only 13% of the patients with a lateralization ACTH <1.4 ratio had a midline tumor) (McCance *et al.* 1989). Surprisingly, Colao *et al.* reported BIPSS was less reliable in identifying the adenoma site found at surgery than MRI or CT (65% vs. 75% and 79%, respectively) (Colao *et al.* 2001). Research discussed that three parameters would interact with the lateralization results: the venous drainage pattern, the sampling selective bias and the CRH stimulation (McCance *et al.* 1989). Based on these factors, our series may due to the former two factors, for the unavailable use of CRH stimulation.

Review the literature, we emphasized that the localization of pituitary micro-adenomas using BIPSS still remains controversial. Regarding lateralization data estimate was poor, but in our series, unilateral ratio (sensitivity as 56.3% and 57.9% respectively) is well below the degree of certainty required by the neurosurgeon to perform a TSS with a micro-adenoma is found at surgical exploration. To avoid these rare pitfalls, for permanence of hypercortisolism be confirmed just before BIPSS, then thoracic and abdominal CT scans or even PET-CT were commend to be systematically performed before BIPSS.

In conclusion, based on the data presented in our study, BIPSS is highly sensitive and specific for accurately diagnosing pituitary CS and may be helpful in lateralizing the location of the adenoma. The procedure was safe and well tolerated. If the procedure is not to be performed in all cases, then it is essential that stringent response criteria are applied to whatever alternative tests are used, and preferably a positive response

to more than one indirect test should be sought before referring a patient for surgery. This means that a significant proportion of patients will still require BIPSS. For pituitary adenomas in CD are usually small and difficult to visualize, combined with the accuracy and efficacy, therefore BIPSS is considered as the most valuable standard for identifying the pituitary gland as the source of ACTH secretion in CD. Nevertheless, despite the improved diagnostic characteristics of BIPSS, we still think that clinical judgment should remain the “gold standard” for the safety and benefit of our Cushing’s patients.

ACKNOWLEDGMENTS

We acknowledge the collaborative support of the endocrinologists, pathologists, radiologists and anesthesiologists at our center. We also acknowledge the seminal contributions to this study by our mentor and colleague, Prof. Tianxi Zhang (Department of Neurosurgery, Ruijin Hospital, Shanghai Jiao Tong University School of Medicine), who developed the study of Cushing’s disease for so much of what has followed.

Author disclosure statement

No conflict of interest.

REFERENCES

- 1 Alzahrani AS, Farhat R, Al-Arifi A, Al-Kahtani N, Kanaan I, Abou-ized M (2009). The diagnostic value of fused positron emission tomography/computed tomography in the localization of adrenocorticotropin-secreting pituitary adenoma in Cushing’s disease. *Pituitary*. **12**: 309–314.
- 2 Blunt SB, Sandler LM, Burrin JM, Joplin GF (1990). An evaluation of the distinction of ectopic and pituitary ACTH dependent Cushing’s syndrome by clinical features, biochemical tests and radiological findings. *Q J Med*. **77**: 1113–1133.
- 3 Bonelli FS, Huston J 3rd, Carpenter PC, Erickson D, Young WF Jr, Meyer FB (2000). Adrenocorticotrophic hormone-dependent Cushing’s syndrome: sensitivity and specificity of inferior petrosal sinus sampling. *AJNR Am J Neuroradiol*. **21**: 690–696.
- 4 Booth GL, Redelmeier DA, Grosman H, Kovacs K, Smyth HS, Ezzat S (1998). Improved diagnostic accuracy of inferior petrosal sinus sampling over imaging for localizing pituitary pathology in patients with Cushing’s disease. *J Clin Endocrinol Metab*. **83**: 2291–2295.
- 5 Colao A, Faggiano A, Pivonello R, Pecori Giraldi F, Cavagnini F, Lombardi G (2001). Inferior petrosal sinus sampling in the differential diagnosis of Cushing’s syndrome: results of an Italian multicenter study. *Eur J Endocrinol*. **144**: 499–507.
- 6 Crapo L (1979). Cushing’s syndrome: a review of diagnostic tests. *Metabolism*. **28**: 955–977.
- 7 Ezzat S, Asa SL, Couldwell WT, Barr CE, Dodge WE, Vance ML, et al (2004). The prevalence of pituitary adenomas: a systematic review. *Cancer*. **101**: 613–619.
- 8 Findling JW, Aron DC, Tyrrell JB, Shinsako JH, Fitzgerald PA, Norman D, et al (1981). Selective venous sampling for ACTH in Cushing’s syndrome: differentiation between Cushing’s disease and the ectopic ACTH syndrome. *Ann Intern Med*. **94**: 647–652.
- 9 Findling JW, Kehoe ME, Shaker JL, Raff H (1991). Routine inferior petrosal sinus sampling in the differential diagnosis of ACTH-dependent Cushing’s syndrome; early recognition of the occult ectopic ACTH syndrome. *J Clin Endocrinol Metab*. **73**: 408–413.
- 10 Findling JW, Raff H (2006). Cushing’s syndrome: important issues in diagnosis and management. *J Clin Endocrinol Metab*. **91**: 3746–3753.
- 11 Gazioglu N, Ulu MO, Ozlen F, Albayram S, Islak C, Kocer N, et al (2008). Management of Cushing’s disease using cavernous sinus sampling: Effectiveness in tumor lateralization. *Clin Neurol Neurosurg*. **110**: 333–338.
- 12 Isidori AM, Kaltsas GA, Pozza C, Frajese V, Newell-Price J, Reznek RH, et al (2006). The ectopic adrenocorticotropin syndrome: clinical features, diagnosis, management, and long term follow-up. *J Clin Endocrinol Metab*. **91**: 371–377.
- 13 Jehle S, Walsh JE, Freda PU, Post KD (2008). Selective use of bilateral inferior petrosal sinus sampling in patients with adrenocorticotropin-dependent Cushing’s syndrome prior to transphenoidal surgery. *J Clin Endocrinol Metab*. **93**: 4624–4632.
- 14 Kaltsas GA, Giannulis MG, Newell-Price JD, Dacie JE, Thakkar C, Afshar F, et al (1999). A critical analysis of the value of simultaneous inferior petrosal sinus sampling in Cushing’s disease and the occult ectopic adrenocorticotropin syndrome. *J Clin Endocrinol Metab*. **84**: 487–492.
- 15 Kaskarelis IS, Tsatalou EG, Benakis SV, Malagari K, Komninos I, Vassiliadi D, et al (2006). Bilateral inferior petrosal sinuses sampling in the routine investigation of Cushing’s syndrome: a comparison with MRI. *AJR Am J Roentgenol*. **187**: 562–570.
- 16 Kennedy L, Atkinson AB, Johnston H, Sheridan B, Hadden DR (1984). Serum cortisol concentrations after low dose dexamethasone suppression to screen for Cushing’s syndrome. *Br Med J (Clin Res Ed)*. **289**: 1188–1191.
- 17 Lefournier V, Martinie M, Vasdev A, Bessou P, Passagia JG, Labat-Moleur F (2003). Accuracy of bilateral inferior petrosal or cavernous sinuses sampling in predicting the lateralization of Cushing’s disease pituitary microadenoma: influence of catheter position and anatomy of venous drainage. *J Clin Endocrinol Metab*. **88**: 196–203.
- 18 Machado MC, de Sa SV, Domenice S, Fragoso MC, Puglia P Jr, Pereira MA, et al (2007). The role of desmopressin in bilateral and simultaneous inferior petrosal sinus sampling for differential diagnosis of ACTH-dependent Cushing’s syndrome. *Clin Endocrinol (Oxf)*. **66**: 136–142.
- 19 Mamelak AN, Dowd CF, Tyrrell JB, McDonald JF, Wilson CB (1996). Venous angiography is needed to interpret inferior petrosal sinus sampling data for lateralizing adrenocorticotropin-secreting adenomas. *J Clin Endocrinol Metab*. **81**: 475–481.
- 20 McCance DR, McIlrath E, McNeill A, Gordon DS, Hadden DR, Kennedy L, et al (1989). Bilateral inferior petrosal sinus sampling as a routine procedure in ACTH-dependent Cushing’s syndrome. *Clin Endocrinol (Oxf)*. **30**: 157–166.
- 21 Meier CA, Biller BM (1997). Clinical and biochemical evaluation of Cushing’s syndrome. *Endocrinol Metab Clin North Am*. **26**: 741–762.
- 22 Newell-Price J, Bertagna X, Grossman AB, Nieman LK (2006). Cushing’s syndrome. *Lancet*. **367**: 1605–1617.
- 23 Newell-Price J, Trainer P, Besser M, Grossman A (1998). The diagnosis and differential diagnosis of Cushing’s syndrome and pseudo-Cushing’s states. *Endocr Rev*. **19**: 647–672.
- 24 Oldfield EH, Doppman JL, Nieman LK, Chrousos GP, Miller DL, Katz DA, et al (1991). Petrosal sinus sampling with and without corticotropin-releasing hormone for the differential diagnosis of Cushing’s syndrome. *N Engl J Med*. **325**: 897–905.
- 25 Oldfield EH, Girton ME, Doppman JL (1985). Absence of intercavernous venous mixing: evidence supporting lateralization of pituitary microadenomas by venous sampling. *J Clin Endocrinol Metab*. **61**: 644–647.
- 26 Orth DN (1995). Cushing’s syndrome. *N Engl J Med*. **332**: 791–803.
- 27 Teramoto A, Yoshida Y, Sanno N, Nemoto S (1998). Cavernous sinus sampling in patients with adrenocorticotrophic hormone-dependent Cushing’s syndrome with emphasis on inter- and intracavernous adrenocorticotrophic hormone gradients. *J Neurosurg*. **89**(5): 762–768.

- 28 Testa RM, Albiger N, Occhi G, Sanguin F, Scanarini M, Berlucchi S, et al (2007). The usefulness of combined biochemical tests in the diagnosis of Cushing's disease with negative pituitary magnetic resonance imaging. *Eur J Endocrinol.* **156**: 241–248.
- 29 Tritos NA, Biller BM, Swearingen B (2011). Management of Cushing disease. *Nat Rev Endocrinol.* **7**: 279–289.
- 30 Tsagarakis S, Vassiliadi D, Kaskarelis IS, Komninos J, Souvatzoglou E, Thalassinou N (2007). The application of the combined corticotrophin-releasing hormone plus desmopressin stimulation during petrosal sinus sampling is both sensitive and specific in differentiating patients with Cushing's disease from patients with the occult ectopic adrenocorticotropin syndrome. *J Clin Endocrinol Metab.* **92**: 2080–2086.
- 31 Wiggam MI, Heaney AP, McIlrath EM, McCance DR, Sheridan B, Hadden DR, et al. (2000). Bilateral inferior petrosal sinus sampling in the differential diagnosis of adrenocorticotropin-dependent Cushing's syndrome: a comparison with other diagnostic tests. *J Clin Endocrinol Metab.* **85**: 1525–1532.