

Transverse testicular ectopia with abnormal karyotype

Jerzy HARASYMCZUK¹, Dominika KAMINIARCZYK-PYZALKA², Maciej KRAWCZYNSKI^{3,4}, Marek NIEDZIELA², Ryszard WAŚKO⁵, Agata CZARNYWOJTEK⁵, Andrzej JANKOWSKI¹

1 Department of Pediatric Surgery, Traumatology and Urology, University of Medical Sciences in Poznan, Poland

2 Department of Pediatric Endocrinology and Rheumatology, University of Medical Sciences in Poznan, Poland

3 Department of Medical Genetics, University of Medical Sciences in Poznan, Poland,

4 GENESIS - Center for Medical Genetics, Poznan, Poland

5 Department of Clinical Endocrinology, Metabolism and Internal Disease, University of Medical Sciences in Poznan, Poland

Correspondence to: Jerzy Harasymczuk MD., PhD.
University of Medical Sciences,
Department of Pediatric Surgery, Traumatology and Urology
Szpitalna street 27/33, 60-572 Poznan, Poland.
TEL/FAX: +48 61 847 52 28; E-MAIL: harasymczuk@o2.pl

Submitted: 2011-04-18 *Accepted:* 2011-05-16 *Published online:* 2011-08-29

Key words: **transverse testicular ectopia; karyotype**

Neuroendocrinol Lett 2011;32(4):408-410 PMID: 21876487 NEL320411C01 © 2011 Neuroendocrinology Letters • www.nel.edu

Abstract

OBJECTIVES: Growth disturbances and developmental malformations of external genitalia, such as hypospadias, bifid scrotum and micropenis, coexisting with non-palpable testes, may develop as a result of primary endocrinological dysfunctions as well as an effect secondary to chromosomal aberrations. Therefore, patients with these symptoms require specific diagnostic and therapeutic approaches.

DESIGN AND METHODS: We present an example of TTE as a presentation of karyotype abnormalities. Clinical presentation – 9.5 year old boy presented with hypospadias, bilateral cryptorchidism and right inguinal hernia and short stature.

RESULTS: Endocrine test showed low testosterone levels with adequate gonadal response. Laparoscopy was performed and revealed the presence of TTE.

CONCLUSIONS: The presence of mosaic karyotype with abnormal Y chromosome does not exclude a possibility of testis migration disorders, including TTE, caused by other (possibly genetic) factors. Laparoscopy is a technique of choice for diagnosis and treatment in cases of cryptorchidism.

Abbreviations:

TTE - transverse testicular ectopia
LH - luteinizing hormone
hCG - human chorionic gonadotropin
IGF-1 - insulin-like growth factor -1

INTRODUCTION

Growth disturbances and developmental malformations of genitals, such as hypospadias, bifid scrotum and micropenis, co-occurring with non-palpable testes, may develop as a result of primary endocrinological dysfunctions, as well as an effect secondary to chromosomal aberrations. Therefore, patients with these symptoms require specific diagnostic and therapeutic approaches. Operative treatment is, in some cases, necessary and is

of high importance, especially in first years of life, due to the possibility of diagnosing gonadoblastoma at an early developmental stage. Karyotype abnormalities were identified and described.

CASE PRESENTATION

Nine and a half year old boy with male phenotype was admitted to the Department of Pediatric Surgery due to right cryptorchidism. The patient was born from III pregnancy, III labor by Cesarean section in 36th week due to transverse position of fetus; birth weight 2,050 g and Apgar score 8/9/10. After birth the boy was diagnosed with hypospadias, bilateral cryptorchidism and right inguinal hernia, clinically presenting as scrotum asymmetry. After admission, ultrasound examination confirmed the absence of right testis in scrotum, and showed the presence of the left testis with the normal ultrasonographic appearance. Laboratory tests showed low basal LH (0 mIU/ml) and testosterone levels (0.1 nmol/l), however a test with hCG resulted with an adequate gonadal response (testosterone level increased to 3.13 nmol/l). No significant concentrations of neoplastic markers (CEA, AFP, B-hCG) were found. Diagnostics conducted prior to admission to the Department of Pediatric Endocrinology revealed short stature (hSDS=-4.6).

Due to the lack of availability of parental anthropometric data, it was impossible to evaluate parental height prognosis, but on the basis of the skeletal age final height was estimated as 147.6 cm (according to Bayley & Pinneau 1952). Normal growth hormone secretion during sleep (24.3 μ IU/ml, 33.4 μ IU/ml, 18.9 μ IU/ml, 20.5 μ IU/ml) and IGF-1 concentrations (149 ng/ml, 30-40 age percentile). At the age of 7 years and 10 months, IGF-1 concentration was 168 ng/ml (80-90 percentiles).

The above results ruled out endocrinological malfunction as the cause for short stature and therefore karyotyping was performed. The following evaluation revealed the presence of a mosaic karyotype with two cell lines: pure monosomy X and dicentric Y isochromosome of short and small part of long arms - 45, X/46, X, idic(Y)(q11.21).

In clinical evaluation after admission to the Department of Pediatric Surgery the following symptoms were present: scars in inguinal regions suggesting previous surgical treatment, scrotal abnormalities (right side hypoplasia), coronal hypospadias with incomplete foreskin. The presence of left testis in scrotum was confirmed by palpation. Furthermore, the presence of a non-painful mass in the left inguinal canal and umbilical hernia were diagnosed. The patient was qualified for laparoscopy. After performing mini-laparotomy according to Hasson method (Hasson 1971; Tosson *et al.* 2010), a trocar with 5 mm, 0 degree optics was introduced. Left inguinal hernia was confirmed. Right testicular vessels and the spermatic duct before entering

right deep inguinal ring (Figure 4) crossed to the left on the fundus of bladder and entered left inguinal canal (Figure 3). Left testicular vessels and spermatic duct showed no abnormalities. The right testis (Transverse Testicular Ectopia) located behind inguinal ring was dissected. Morphologically, it showed signs of severe underdevelopment (Figure 1).

A decision to perform a complete testicular resection including vessels and the spermatic duct and left hernia repair was made (Figure 2). Cryptorchidic gonad was verified by histopathology - result: *fibroadipose tissue fragments, showing spermatic cord elements and testis with signs of atrophy.*

DISCUSSION

Mosaic karyotype with presence of 45,X cell line and one or more cell lines containing Y chromosome (with normal or abnormal structure) is one of the main causes leading to developmental disorders of gonads (Committee on Genetics 2000). Patients with mosaic karyotype 45,X/46,XY manifest diverse range of phenotypes - from females with Turner syndrome and bilateral fibrous strands in place of ovaries, through patients with mixed dysgenesis of gonads, to males with fully developed testes (Knudtzon & Aarskog 1987; Kelly *et al.* 1998; Telvi *et al.* 1999). It is known that sex determination in patients with sex chromosome mosaicism is based mainly on the dominant cell line present in a non-differentiated gonad (45,X - Turner syndrome, 46,XY - male phenotype, both cell lines - mixed gonad dysgenesis) (Kelly *et al.* 1998).

Structural abnormalities or absence of chromosome Y fragment are additional factors leading to developmental disorders of genitalies (hypospadias, bifid scrotum and small penis coexisting with cryptorchidism). One of the most common chromosome Y structural anomalies is its dicentricity. Dicentric Y chromosomes are unstable during mitosis and are lost during some cell divisions causing mosaicism, most commonly with 45,X cell line. Karyotype screening is usually based on the analysis of peripheral blood lymphocytes. In many cases, however, lymphocytes dominant cell line is not equivalent to the dominant cell line present in gonads and responsible for sex determination. This explains phenotype diversity in children with mosaic 45,X/46,XY karyotype.

The most commonly observed somatic anomaly in patients with mosaic 45, X/46,XY karyotype is short stature. It appears that growth is suppressed mainly on the basis of the presence of dominant 45,X cell line leading to impaired gonad function (no pubertal growth spurt).

The short arm of Y chromosome contains the SRY gene, responsible for male sex determination and the long arm contains a cluster of genes (AZF regions) responsible for spermatogenesis and male fertility, thus, in our patient 46, X, idic(Y) (q11.21) his male genital

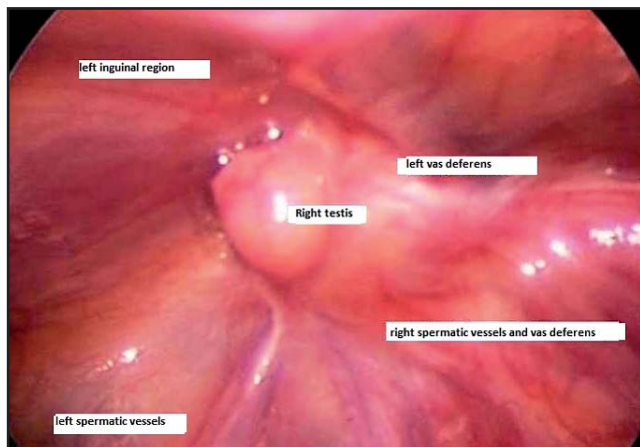


Fig. 1. The right testis (Transverse Testicular Ectopia) located behind inguinal ring was dissected. Morphologically, it showed signs of severe underdevelopment.

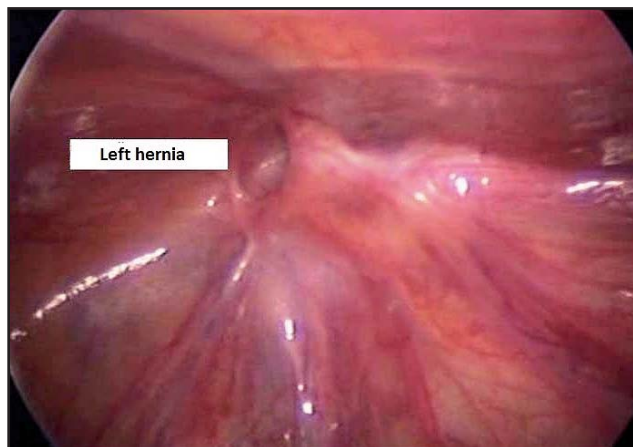


Fig. 2. A decision to perform a complete testicular resection including vessels and the spermatic duct and left hernia repair was made.

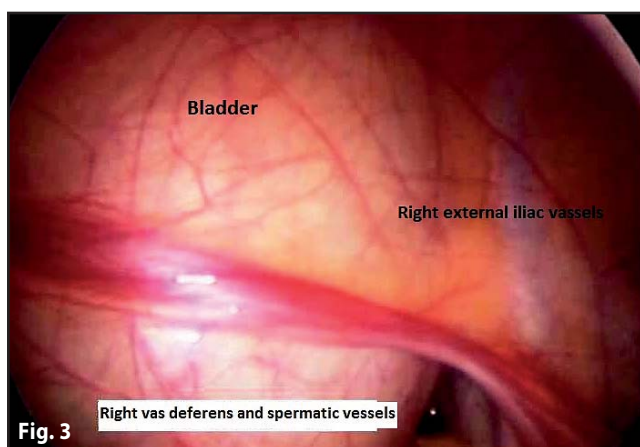


Fig. 3

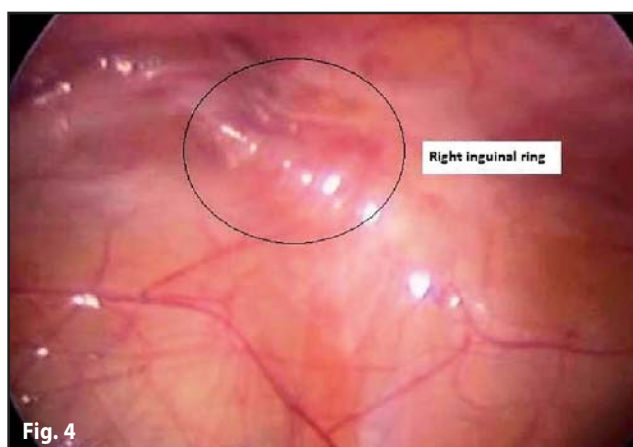


Fig. 4

Fig. 3 and 4. Right testicular vessels and the spermatic duct before entering right deep inguinal ring (Fig. 4) crossed to the left on the fundus of bladder and entered left inguinal canal (Fig. 3).

sex is justified but future azoospermia and infertility can be expected.

CONCLUSIONS

Dominant 45,X cell line in patients with male phenotype and mosaic sex chromosome aberration is a cause for short stature and may lead to sex determination disturbances.

Second cell line with dicentric Y chromosome [46, X, idic(Y) (q11.21)] is responsible for male phenotype determination but with co-occurring azoospermia due to the lack of the AZF region.

The presence of mosaic karyotype with an abnormal Y chromosome does not exclude the possibility of testis migration disorders including TTE caused by other (possibly genetic) factors.

In the case in point, the presence of mosaic karyotype 45, X/46, X, idic(Y), external genital abnormalities (hypospadias, micropenis, scrotum abnormalities) and testis migration disturbances increase the potential risk for developing a primary testis tumor. Therefore,

regular follow-ups with high oncological vigilance is required.

Laparoscopy is a technique of choice for diagnosis and treatment in cases of cryptorchidism.

REFERENCES

- 1 Committee on Genetics, Section on Endocrinology, and Section on Urology. Pediatrics (2000) American Academy of Pediatrics: Evaluation of the newborn with developmental anomalies of the external genitalia. **106**: 138–142.
- 2 Hasson HM (1971) A modified instrument and method for laparoscopy. *Am J Obstet Gynaecol.* **110**: 886–7.
- 3 Kelly TE, Franko JB, Rogol A, Golden WL (1998) Discordant phenotypes and 45,X/46,X,idic(Y). *J Med Genet.* **35**: 862–864.
- 4 Knudtson J, Aarskog D (1987) 45,X/46,XY mosaicism. A clinical review and report of ten cases. *Eur J Pediatr.* **146**: 266–271.
- 5 Telvi L, Lebbar A, Del Pino O, Barbet JP, Chaussain JL (1999) 45,X/46,XY mosaicism: report of 27 cases. *Pediatrics.* **104**: 304–308.
- 6 Tosson H, Rose SR, Gartner LA (2010). Children with 45,X/46,XY karyotype from birth to adult height. *Horm Res Paediatr.* **74**: 190–200.