

# An endovascular treatment of Chronic Cerebro-Spinal Venous Insufficiency in Multiple Sclerosis patients – 6 month follow-up results

Jacek KOSTECKI<sup>2</sup>, Maciej ZANIEWSKI<sup>2</sup>, Krzysztof ZIAJA<sup>1</sup>, Tomasz URBANEK<sup>1</sup>,  
Wacław KUCZMIK<sup>1</sup>, Ewa KRZYSTANEK<sup>3</sup>, Damian ZIAJA<sup>1</sup>, Tomasz KORZENIOWSKI<sup>2</sup>,  
Eugeniusz MAJEWSKI<sup>2</sup>, Marcin HARTEL<sup>4</sup>, Maciej ŚWIAT<sup>3</sup>, Urszula SIOMA-MARKOWSKA<sup>5</sup>

- 1 Department of General and Vascular Surgery, Medical University of Silesia, Katowice, Poland
- 2 Department of Surgery, Medical University of Silesia, District Specialist Hospital, Tychy, Poland
- 3 Department of Neurology, Aging, Vascular and Neurodegenerative Diseases, Central University Hospital, Medical University of Silesia, Katowice, Poland
- 4 Medical Diagnostic Centers Voxel, Zabrze, Poland
- 5 Department Of Gynecology and Obsterics, Medical University of Silesia, Tychy, Poland

*Correspondence to:* Jacek Kostecki, MD.  
Department of Surgery, Specialist Hospital,  
Edukacji 102, 43-100 Tychy, Poland.  
TEL: +48 32 3254245; E-MAIL: kosteckj@op.pl

*Submitted:* 2011-04-02 *Accepted:* 2011-05-04 *Published online:* 2011-08-29

*Key words:* CCSVI; multiple sclerosis; vein angioplasty; quality of life

Neuroendocrinol Lett 2011;32(4):557-562 PMID: 21876515 NEL320411A17 © 2011 Neuroendocrinology Letters • www.nel.edu

## Abstract

**OBJECTIVE:** In this study, the mid-term results (6 month follow-up) of the endovascular treatment in patients with Chronic Cerebro-Spinal Venous Insufficiency (CCSVI) and multiple sclerosis (MS) were prospectively evaluated.

**METHODS:** Thirty-six patients with confirmed MS and CCSVI underwent endovascular treatment by the means of the uni- or bilateral jugular vein angioplasty with optional stent placement. All the patients completed 6 month follow-up. Their MS-related disability status and quality of life were evaluated 1, 3 and 6 months postoperatively by means of the following scales: Expanded Disability Status Scale (EDSS), Multiple Sclerosis Impact Scale (MSIS-29), Epworth Sleepiness Scale (ESS), Heat Intolerance scale (HIS) and Fatigue Severity Scale (FSS). For patency and restenosis rate assessment, the control US duplex Doppler examination was used.

**RESULTS:** Six months after the procedure, restenosis in post-PTA jugular veins was found in 33% of cases. Among 17 patients who underwent stent implantation into the jugular vein, restenosis or partial in-stent thrombosis was identified in 55% of the cases. At the 6 month follow-up appointment, there was no significant improvement in the EDSS or the ESS. The endovascular treatment of the CCSVI improved the quality of life according to the MSIS-29 scale but only up to 3 months after the procedure (with no differences in the 6 month follow-up assessment). Six months after the jugular vein angioplasty (with or without stent placement), a statistically significant improvement was observed only in the FSS and the HIS.

**CONCLUSIONS:** The endovascular treatment in patients with MS and concomitant CCSVI did not have an influence on the patient's neurological condition; however, in the mid-term follow-up, an improvement in some quality-of-life parameters was observed.

## INTRODUCTION

Multiple sclerosis (MS), first described by Charcot in 1846, remains one of the most severe and difficult to treat central nervous system (CNS) pathologies (Charcot 1868). In Poland, an estimated 60,000 patients suffer from MS; however, due to the difficulties related to proper early diagnosis of the disease, the correct number may be even higher. Despite the many studies performed during the past 150 years, the primary pathogenetic factor related to MS development remains unknown. Currently, the most widely-held hypothesis is that the focal CNS lesions observed in MS are the result of an autoimmune reaction (Berilgen *et al.* 2005; Compston & Coles 2008; Martin *et al.* 1992).

Other non-autoimmune factors and disturbances have also been observed in patients with MS. In the 1980s, Schelling first described relationships between local venous system pathology and the occurrence of focal demyelination (Schelling 1986). The clinical studies related to these findings were continued by Paolo Zamboni, who described the term Chronic Cerebro-Spinal Venous Insufficiency (CCSVI) in relation to the presence of stenoses and/or haemodynamical disturbances in the vein outflow from the brain and spinal cord. According to some recent studies, the presence of CCSVI can potentially influence the progression of and, hypothetically, the occurrence of MS (Zamboni *et al.* 2009).

Currently the investigations concerning the relationship between CCSVI and MS are performed in many centres. In some of them an invasive treatment of CCSVI was implemented (Zamboni *et al.* 2009; Zaniewski *et al.* 2010). However, the lack of randomised controlled trials and very poor follow-up data of the treated patients can not currently justify the routine endovascular treatment in these patients.

In our study, the mid-term results (6 month follow-up) of endovascular treatment in patients with Chronic Cerebro-Spinal Venous Insufficiency (CCSVI) and MS were prospectively evaluated.

## METHODS

Thirty-six patients with MS (as diagnosed based on the McDonald criteria) were evaluated. Fifteen women and 21 men with MS were enrolled in the study (time since diagnosis ranged from 1 to 40 years, with a mean of 11 years). The mean age of the participants was 38 years (24–65 years). Eighteen patients were diagnosed with relapsing–remitting MS, 11 patients were diagnosed with secondary progressive MS, and 7 patients were diagnosed with primary progressive MS.

The exclusion criteria were as follows: the presence of CNS vascular malformations, brain or spinal tumours, inflammatory vascular diseases, congenital vascular abnormalities (e.g., Parkes-Weber, Servelle-Martorell and Klippel-Trenaunay syndromes), the pres-

ence of chronic venous insufficiency within the lower or upper extremities, stenoses/occlusions of the supra-aortic arteries or previous TIA or stroke.

Qualification for endovascular treatment was based on the neurological patient assessment and diagnosis of CCSVI according to the performed imaging studies. All of the patients were assessed by an independent neurologist pre- and post-operatively. The clinical assessment, including an evaluation of neurological deficit and severity of disability, was based on the Expanded Disability Status Scale – EDSS (Kurtzke 1983).

The intensity and severity of several MS-related symptoms, as well as their influence on the patients quality-of-life, was evaluated by the following diagnostic tools (scales) based on the patient's self-assessment: Multiple Sclerosis Impact Scale (MSIS-29), Fatigue Severity Scale (FSS), Heat Intolerance Scale (HIS) and Epworth Sleepiness Scale (ESS) (Hobart *et al.* 2001; Johns 1991; Lauren *et al.* 1989).

The presence of CCSVI was diagnosed and confirmed by duplex Doppler US and MR-phlebography. The US examinations of the internal jugular and vertebral veins were performed in sitting and supine positions with a linear probe at 7.5–10 MHz. The evaluation covered vein morphology and vein cross-sectional area as well as an assessment of vein valve competence, flow direction and velocity. The examination also included screening for the following morphological and haemodynamic disturbances: (1) the presence of a pathological valve that leads to a significant haemodynamic slowdown of flow above the valve or the presence of reflux in the internal jugular vein, (2) septum in the vein lumen, vein lumen narrowing or the complete blockage of the flow in the internal jugular vein and (3) the presence of non-physiological outflow of blood from the CNS through the vertebral veins when patients were in a supine position or the lack of a decrease in the cross-section area of the internal jugular vein in a sitting position compared with a supine position. To confirm the observed pathology in each patient, MR phlebography of the CNS draining veins (including azygos vein) was performed.

In all patients from the study group, significant haemodynamical CNS vein outflow disturbances were recognised. The study was approved by the Local Ethics Committee, and informed consent was obtained from all participants. Final treatment decisions considered the results of catheter venography (of the internal jugular, vertebral and azygos veins), which was performed intraoperatively before angioplasty or stent placement. The venography exam was always followed by a pressure gradient measurement that was repeated after haemodynamical correction.

In 56% of cases, bilateral pathology was observed; in the remaining 46% cases, unilateral CNS venous outflow disturbances were found. (Table 1)

Catheter venography was performed using local anaesthesia. Venographic confirmation of the pre-

viously diagnosed vein outflow disturbances was achieved in all subjects, and in all patients, the decision to use balloon angioplasty (with balloon size of 10 – 14×40 mm) of the internal jugular vein stenosis was made after venography.

In 13 patients, PTA of both internal jugular veins had to be performed, and in the remaining 23 patients, unilateral pathology was treated. In 17 cases with no or suboptimal haemodynamical improvement after PTA at the level of the proximal internal jugular vein valve, the procedure was continued with self-expandable stent implantation. In all of these cases, 12×40 mm or 14×40 mm SMART stents (Cordis) were used (10 on the right side and 7 on the left side). All patients were treated postoperatively with dual antiplatelet therapy and a 14 day course of therapeutic doses of low molecular weight heparin.

Among the treated patients, 100% completed the 6 month follow-up evaluation. The control assessments were provided 1, 3 and 6 months after the procedure. In all the cases, independent neurological assessments and the quality-of-life evaluations were performed during each control visit. For the patency and restenosis rate assessment, the control US duplex Doppler examination was used.

The U Mann-Whitney statistical analysis test was used to compare neurological scale rates.

## RESULTS

In the group of 36 endovascularly treated patients, no perioperative treatment-related complications were observed. The mean decrease of vein pressure in the jugular veins was 3.5 cm H<sub>2</sub>O on the left and 4.5 cm H<sub>2</sub>O on the right (Figure 1).

In the doppler US performed 6 months after the procedure, restenosis of the treated internal jugular

**Tab. 1.** The frequency of the reported pathologies in the CNS venous outflow

Pathological valve in the internal jugular vein	25/36	<b>69%</b>
Septum in the internal jugular vein	5/36	<b>14%</b>
Internal jugular vein stenosis *	25/36	<b>69%</b>
Complete blockage of the outflow through the internal jugular vein	5/36	<b>14%</b>
An increase of the vertebral vein flow**	11/36	<b>31%</b>
Internal jugular vein reflux (pathological) in the sitting position ***	7/36	<b>19%</b>

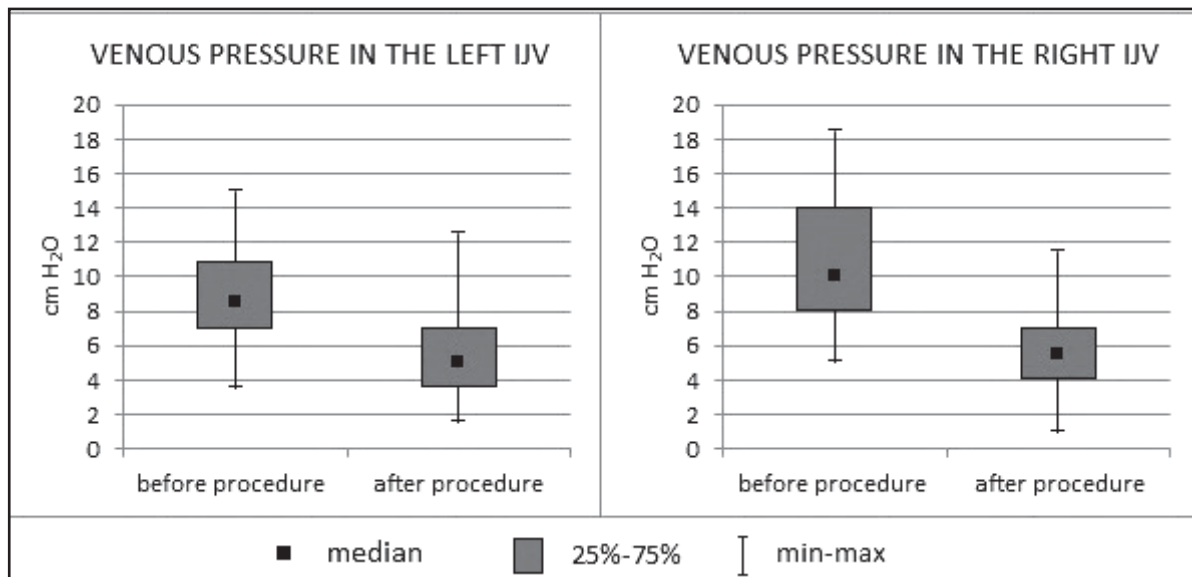
\* focal internal jugular vein stenosis (cross sectional area ≤0, 3 cm<sup>2</sup>)

\*\* an increase of the vertebral vein flow (> 60 ml/min), as an alternative (non-physiological) way of the CNS venous outflow in supine position

\*\*\* the lack of the internal jugular vein physiological cross-sectional area decrease in the sitting position (in comparison to the supine position)

veins was observed in 12 patients (33%). Among the 17 patients that underwent stent placement into an internal jugular vein, 10 cases (59%) had in-stent restenosis or thrombosis (in two of cases, total stent occlusion was diagnosed).

In the neurological assessment, there were no statistically significant differences in the EDSS or in the ESS when comparing the pre-operative and 6 month follow-up evaluations (Figures 2 and 3). The endovascular treatment of the CCSVI improved the quality of life according to the MSIS-29 (a decrease of the score from 90 to 73.5) but only up to 3 months after procedure, with no differences in the 6 month follow-up assessment (Figure 4). Six months after the jugular vein angioplasty (with or without stent placement), a statistically significant improvement was observed only



**Fig. 1.** Vein pressure in the internal jugular veins before and after haemodynamical endovascular correction.

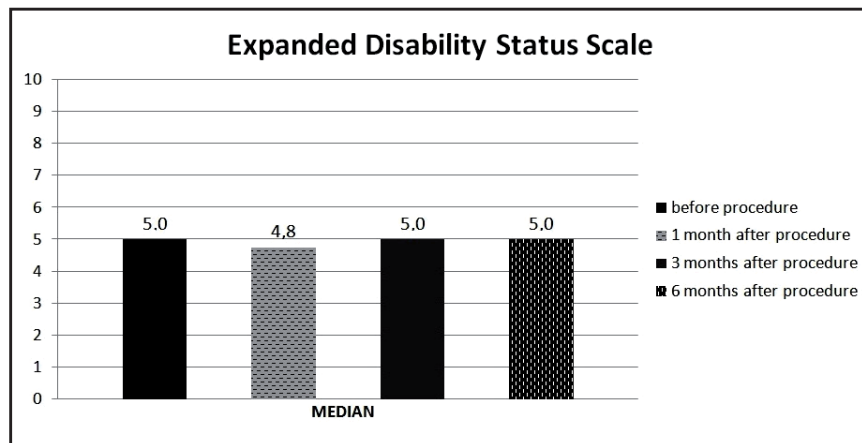


Fig. 2. EDSS before and after endovascular treatment (6 month follow-up).

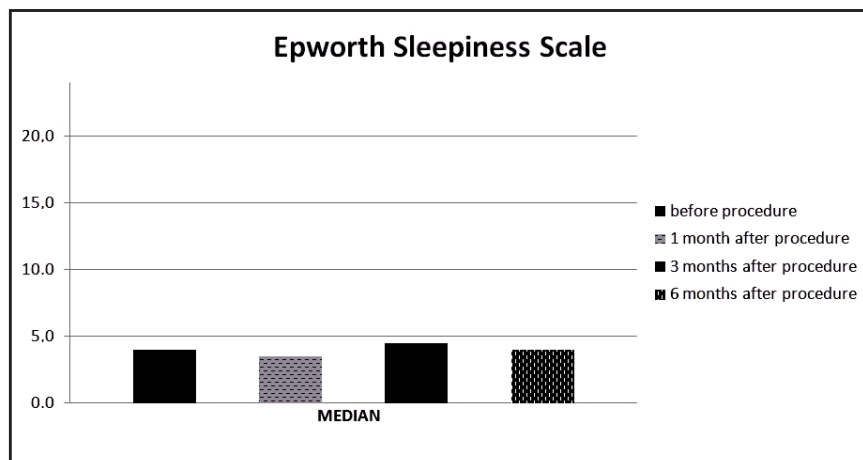


Fig. 3. Epworth Sleepiness Scale before and after endovascular treatment (6 month follow-up).

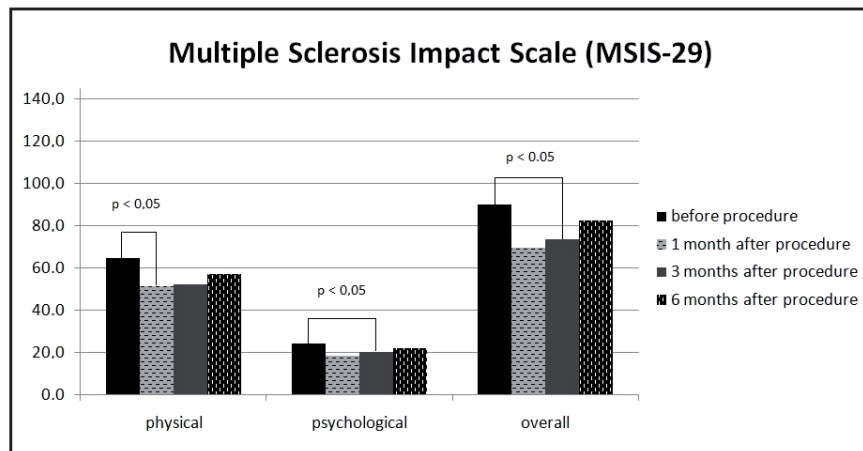


Fig. 4. MSIS-29 before and after endovascular treatment (6 month follow-up).

in the FSS (the mean score decreased from 49.5 to 36 in a 63 point scale) as well as in the HIS (the mean score decreased from 3.5 to 3 in the 5-point scale of heat intolerance (Figures 5 and 6).

In the follow-up examinations, the lack of restenosis did not improve the evaluation results 6 months after the procedure. An occurrence of restenosis or stent occlusion did not result in any statistically significant differences (in comparison with no-restenosis group) in the 6 month follow-up assessment performed according to the study protocol.

## DISCUSSION

A growing number of studies describing the potential relationship between vascular, especially venous, pathology and MS have not definitively answered the question concerning the aetiology and pathomechanism of the disease's development (Zamboni *et al.* 2009). Coexistence of CNS venous outflow abnormalities in patients with MS and the presence of CCSVI in this group of patients was confirmed by some previous authors, although there are also studies suggesting the lack of such a relationship in MS patients (Al-Omari & Rousan 2010; Doepp *et al.* 2010; Zamboni *et al.* 2009). The potential factors that can influence this situation are the lack of a unified criteria concerning CCSVI diagnosis, the heterogeneity of patient populations in terms of neurological deficits, CNS injury and observed local venous pathology.

In the described cohort, the changes characteristic for CCSVI were observed and diagnosed according to two independent imaging studies: US duplex Doppler and MR phlebography. The presence of previously found abnormalities was confirmed by invasive phlebography, which should be considered as the "gold standard" diagnostic modality for this kind of pathology. The group of 36 patients discussed in the study represents a subgroup of MS patients screened and diagnosed in our centre. According to our experience and observations based on the US Doppler evaluation of the group of 350 MS patients and 100 healthy volunteers, CNS vein outflow disturbances related to the CCSVI could be found in 84% of the MS subjects and 14 % of healthy individuals (data not shown—paper submitted for publication).

The possibility of CCSVI endovascular treatment and CNS venous outflow improvement led to an implementation of the invasive treatment in some vascular centres in Europe and the US. Despite the growing number of patients under-



going vein angioplasty, there is still very little data describing the outcomes of available treatments. The lack of randomisation, the relatively short follow-up and the difficulties related to proper result assessment decrease the chance for proper treatment efficacy evaluation. In a study published by Zamboni *et al.* (2009), 65 patients underwent PTA of the internal jugular or azygos veins because of CCSVI. An angioplasty of the venous structures positively influenced the clinical and quality-of-life parameters of CCSVI-associated MS only in the relapsing-remitting MS subgroup, with no influence on the other MS courses (primary or secondary progressive MS) (Zamboni *et al.* 2009). Unfortunately, in our study, we could only partially confirm these results, especially regarding chronic fatigue. The positive influence of the performed procedure related to the decrease in patient disability and quality-of-life improvements noticed within 3 months in MSIS-29 could be not found in the further follow-up (6 months after angioplasty). In the 6 month follow-up evaluation, we did not observe any improvement according to the EDSS and ESS.

In Zamboni's study, restenosis of the internal jugular vein was observed in 47% of cases – the authors also suggest a significant influence of restenosis occurrence on disease progression (Zamboni *et al.* 2009). In our study, despite a 33% restenosis rate 6 months after the procedure, there were no differences concerning the clinical course and the performed assessment results in the group of patients with or without restenosis. Due to the relatively small number of patients that completed the 6 month follow-up, we were not able to perform an analysis according to MS course (primary progressive, secondary progressive, relapsing-remitting).

One of the main disadvantages of the proposed treatment is the invasive character of the procedure. In our study of 36 patients, there were no early complications related

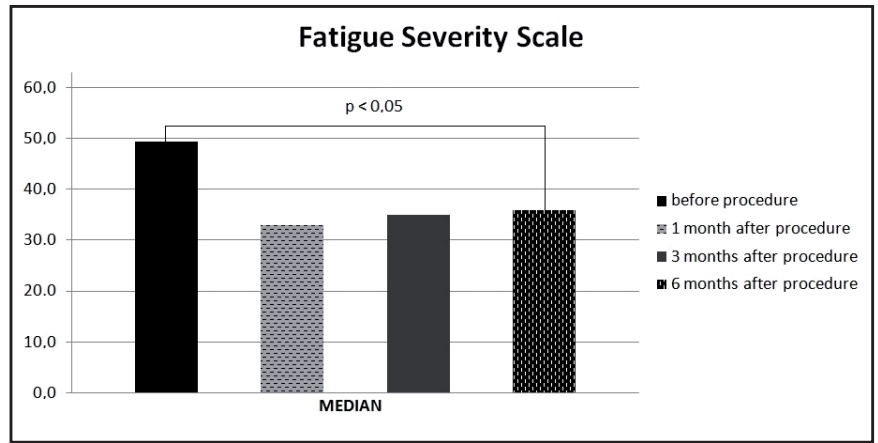


Fig. 5. FSS before and after endovascular treatment (6 month follow-up).

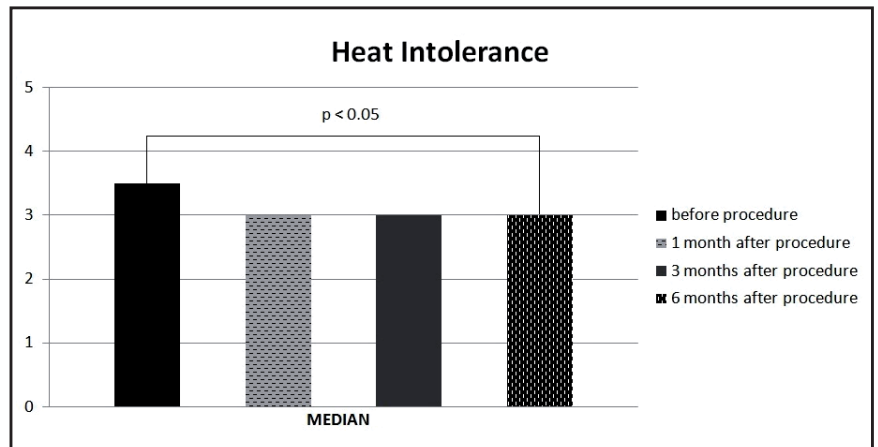


Fig. 6. HIS before and after endovascular treatment (6 month follow-up).

to the preformed endovascular treatment (however, as mentioned above, in the follow-up, restenosis and 2 stent occlusions were noticed). Ludyga and co-workers did not observe any serious complications related to CCSVI endovascular treatment in 331 patients aside from thrombosis in 2 stents. In their study, one additional patient required surgical balloon removal from the femoral vein, and in a few cases local technical problems such as a punctured side, a bleeding alimentary tract, and arrhythmias were observed (Ludyga *et al.* 2010). At this time, a lack of consensus concerning postoperative antithrombotic treatment should also be mentioned. In our cohort, all patients received dual antiplatelet therapy as well as a 2-week course of low molecular weight heparin. The presence of the partial or whole lumen in in-stent thrombosis suggests that such a treatment cannot be sufficient in patients undergoing internal jugular vein stent placement. The relatively low pressure gradient as well as very special haemodynamical conditions in the upper body differ significantly from those noticed in the lower extremities. Taking this into account, an avoidance of stent placement in this setting (if possible) should be proposed. On the other hand, in patients who underwent stent implantation into the internal jugular vein, a prolonged (in not lifelong) anticoagulant therapy should be taken into consideration. In our study all of the patients with diagnosed in-stent thrombosis were immediately switched to oral anticoagulant treatment.

Despite the non-conclusive results concerning potential neurological improvement in CCSVI patients suffering from MS, improvements related to chronic fatigue and heat intolerance encouraged us to continue the study. The need for longer follow-up evaluations and the necessity of the study

performed on larger groups of patients with various MS courses should be emphasised. One of the most important problems to resolve is also the potential placebo effect in patients qualifying for endovascular treatment. In our study, the positive effect of the performed procedure in the MSIS-29 observed 3 months after endovascular treatment had disappeared by 6 months after the procedure.

Currently, we are not able to determine which group of CCSVI patients will achieve the biggest clinical and quality-of-life improvements when treated by endovascular methods. We also do not know whether it can significantly influence further MS progression in the late follow-up evaluations. Taking into account the growing number of endovascularly-treated patients and the methodology and quality of available studies, an urgent need for a well-designed randomised controlled trial should be emphasised. The need for CCSVI diagnostic criteria unification should also be considered urgent.

## CONCLUSIONS

Endovascular treatment in patients with MS and concomitant CCSVI did not influence the patients' neurological conditions; however, in the mid-term follow-up an improvement concerning some parameters influencing the patients' quality-of-life were observed.

## REFERENCES

- 1 Al-Omari MH, Rousan LA (2010) Internal jugular vein morphology and hemodynamics in patients with multiple sclerosis. *Int Angiol.* **29**: 115–20.
- 2 Berilgen MS, Bulut S, Ustundag B, Tekatas A, Ayar A (2005) Patient with multiple sclerosis have higher levels of serum ghrelin. *Neuro Endocrinol Lett.* **26**: 819–22.
- 3 Charcot (1868) Histologie de la sclerose en plaques. *Gaz Hopit Civils Milit.* **41**: 554–566.
- 4 Compston A, Coles A (2008) Multiple Sclerosis. *Lancet.* **372**: 1502–17.
- 5 Doepp F, Paul F, Valdeuza JM, Schmierer K, Schreiber SJ (2010) No cerebrocervical venous congestion in patients with multiple sclerosis. *Ann Neurol.* **68**: 173–83.
- 6 Hobart J, Lamping D, Fitzpatrick R, Riazi A, Thompson A (2001) The Multiple Sclerosis Impact Scale (MSIS-29): a new patient-based outcome measure. *Brain.* **124**: 962–973.
- 7 Johns MW (1991) A new method for measuring daytime sleepiness: the Epworth sleepiness scale. *Sleep.* **14**: 540–5.
- 8 Kurtzke JF (1983) Rating neurological impairment in multiple sclerosis: an expanded disability status scale (EDSS). *Neurology.* **33**: 1444–1452.
- 9 Lauren B, Krupp MD, Nicholas G (1989) The Fatigue Severity Scale. Application to Patients With Multiple Sclerosis and Systemic Lupus Erythematosus. *Arch Neurol.* **46**: 1121–1123.
- 10 Ludyga T, Kazibudzki M, Simka M (2010) Endovascular treatment for chronic cerebrospinal venous insufficiency: is the procedure safe? *Phlebology.* **25**: 286–95.
- 11 Malagoni AM, Galeotti R, Menegatti E, Manfredini F, Basaglia N, Salvi F, et al. (2010) Is chronic fatigue the symptom of venous insufficiency associated with multiple sclerosis? A longitudinal pilot study. *Int Angiol.* **29**: 176–82.
- 12 Martin R, McFarland HF, McFarlin DE (1992) Immunological aspects of demyelinating diseases. *Annu Rev Immunol.* **10**: 153–87.
- 13 Schelling F (1986) Damaging venous reflux into the skull or spine: relevance to multiple sclerosis. *Med Hypotheses.* **21**: 141–8.
- 14 Zamboni P, Galeotti R, Menegatti E, Malagoni AM, Giancesini S, Bartolomei I, et al. (2009) A prospective open-label study of endovascular treatment of chronic cerebrospinal venous insufficiency. *J Vasc Surg.* **50**: 1348–58.
- 15 Zamboni P, Galeotti R, Menegatti E, Malagoni M, Tacconi G, Dall'Ara S, et al. (2009) Chronic cerebrospinal venous insufficiency in patients with multiple sclerosis. *J Neurol Neurosurg Psychiatry.* **80**: 392–9.
- 16 Zamboni P, Menegatti E, Galeotti R, Malagoni AM, Tacconi G, Dall'Ara S, et al. (2009) The value of cerebral Doppler venous haemodynamics in the assessment of multiple sclerosis. *J Neurol Sci.* **282**: 21–7.
- 17 Zaniewski M, Kostecki J, Ziąja K, Kuczmik W, Hartel M, Ziąja D, et al. (2010) Endovascular surgery for the treatment of symptoms of multiple sclerosis. Preliminary report. *Pol Surg.* **1**: 12–17.