

Ultrasound measurements of the transverse diameter of the fetal thymus in uncomplicated singleton pregnancies

Ivana MUSILOVA^{1,2}, Marian KACEROVSKY¹, Tatana RESLOVA¹, Jindrich TOSNER¹

¹ Department of Obstetrics and Gynecology, Charles University in Prague, Faculty of Medicine Hradec Kralove, University Hospital Hradec Kralove, Czech Republic.

² Arleta IVF s.r.o., Kostelec nad Orlici, Czech Republic

Correspondence to: Marian Kacerovsky, MD.
Department of Obstetrics and Gynecology, Charles University in Prague,
Faculty of Medicine Hradec Kralove, University Hospital Hradec Kralove,
Sokolska 581, 500 05 Hradec Kralove, Czech Republic.
TEL: + 420-777657991; FAX: +420-495832676; E-MAIL: kacermar@fnhk.cz

Submitted: 2010-06-25 *Accepted:* 2010-10-29 *Published online:* 2011-01-10

Key words: fetal thymus; ultrasound; prenatal diagnosis; transverse diameter

Neuroendocrinol Lett 2010; 31(6):766–770 PMID: 21196909 NEL310610A07 © 2010 Neuroendocrinology Letters • www.nel.edu

Abstract

OBJECTIVE: To determine sonographically the transverse diameter of the fetal thymus and present nomogram for the transverse diameter of the fetal thymus in uncomplicated singleton pregnancies between 19 and 38 weeks of gestation. Setting: Department of Obstetrics and Gynecology, Charles University in Prague, Faculty of Medicine Hradec Kralove, University Hospital Hradec Kralove, Czech Republic.

METHODS: A prospective study was performed. The transverse diameter of the fetal thymus was measured by the one experienced examiner in 198 healthy fetuses between 19 and 38 weeks of gestation.

RESULTS: The transverse diameters of the fetal thymus were obtained from 183 of the 198 subjects. The regression equation was expressed as a function of gestational age: the transverse diameter of the fetal thymus (mm) = $1.001 \times \text{gestational age (week)} - 0.932$ or $0.143 \times \text{day} - 1.34$. Both the correlation coefficients, $r=0.91$ for weeks and $r=0.92$ for days were found to be highly statistically significant ($p<0.0001$).

CONCLUSION: This study presents normative data (mean, 5th and 95th) for the ultrasound measurements of the transverse diameter of the fetal thymus in healthy singleton pregnancies.

INTRODUCTION

The thymus is a bi-lobed, key organ of the cellular branch of the immune system which plays an important role in the differentiation, selection and maturation of T-cell lymphocytes (Ciofani & Zuniga-Pflucker 2007). The thymic organogenesis begins at the third branchial cleft and the first lymphocytes appear in the thymus during ninth week of gestation (Jeppesen *et al.* 2003). The thymus

grows and enlarges continuously between the prenatal period and puberty. Moreover, during its prenatal development, the size of fetal thymus is in close relationship with T-cell output (Haynes & Heinly 1995).

It is a well known fact that the thymus is susceptible to involution, which can occur in two different ways (Toti *et al.* 2000). First, age related

involution begins in the puberty and the thymus size and its activity are dramatically reduced. Nevertheless, residual T-cells production continues throughout the adult life (Tosi *et al.* 1982). Second, stress involution may appear during the prenatal period in response to different forms of acute stress stimuli such as infection, trauma, sepsis, malnutrition, acute respiratory distress syndrome and physical stress (Toti *et al.* 2000). This type of the thymic involution is initiated by the activation of the hypothalamo-pituitary-adrenal axis which in turn causes glucocorticoids induced apoptosis of cortical thymocytes (Suster & Rosai 1990). The stress thymic involution is histopathologically described by karyorrhexis of lymphocytes with phagocytosis by macrophages. This process proceeds with increasing stimulation, but appears to be reversible in contrast to age related involution (Kendall *et al.* 1985; Toti *et al.* 2000). The stress thymic involution was reported in the presence of histological chorioamnionitis in a radiologic study (De Felice *et al.* 1999), and recently in a ultrasound study (Di Naro *et al.* 2006; El-Haieg *et al.* 2008; Yinon *et al.* 2007) and along with intrauterine growth restricted fetuses (Cromi *et al.* 2009).

These recent studies suggest opportunity to use measurement of transverse diameter of the fetal thymus as potential ultrasound screening tools for the prenatal diagnosis of the stress thymic involution. However, the assessment of the fetal thymus stress involution requires a normative data for transverse thymus diameter at each gestational age.

The main purpose of this study was to sonographically evaluate the transverse diameter of the fetal thymus and establish a nomogram for the transverse diameter of the fetal thymus in uncomplicated singleton pregnancies between 19 and 38 weeks of gestation.

PATIENTS AND METHODS

The study population was established from healthy pregnant women referred for prenatal ultrasound examination. A total of 198 women were recruited consecutively between October 2009 and May 2010. All agreed and provided written informed consent for this study. The study was approved by the Institutional Review Board Committee (March 19, 2008; no. 200804 SO1P). All women enrolled to this study were Caucasians. Only women who fulfilled the following criteria were enrolled: maternal age more than 18 years, singleton pregnancy, certain gestational age as documented by the last menstrual period and corroborated with ultrasound dating, an ultrasound estimated weight of the fetus between the 10th and 90th percentile for gestational age, the absence of the fetal structural malformations or chromosomal abnormalities and the absence of maternal diseases. Exclusion criteria were: pregnancies resulting in newborns with birth weight below the 10th and 90th percentile for the gestational age and the pres-

ence of fetal congenital abnormalities prenatally diagnosed or after birth.

All ultrasound evaluations were performed between 19 and 38 weeks of gestation in one prenatal ultrasound centre. Each subject was examined only during routine examination in the second and the third trimester of the pregnancy using a GE Loqiq P5 (GE Medical Systems, Zipf, Austria) ultrasound device with a transabdominal 2–5 MHz transducer. All women were examined by the same experienced examiner (I.M.).

As previously described (Cho *et al.* 2007) the fetal thymus was found in the transverse section of the fetal chest between the sternum and the great heart vessels (“the three vessels” view) and the maximum transverse diameter of the fetal thymus was measured placing a line cursor upright to junction between the sternum and the spine (Figure 1). Each measurement was repeated three times in each fetus. The mean size was determined and used for statistical analysis.

All statistical analyses were performed using GraphPad Prism 5.03 for Windows (GraphPad Software, USA). The relationships between the transverse diameters of the fetal thymus with gestational ages were determined by linear regression modeling. A Bland-Altman plot of agreement was created for the intraobserver variability. A *p*-value < 0.05 was considered statistically significant.

RESULTS

The results of the fetal thymic transverse diameter measurements were obtained in 183 subjects. Thymus detection ratio was 92% (183/198 fetuses). The linear regression equations for mean transverse diameter of fetal thymus as a function of week and day of ges-

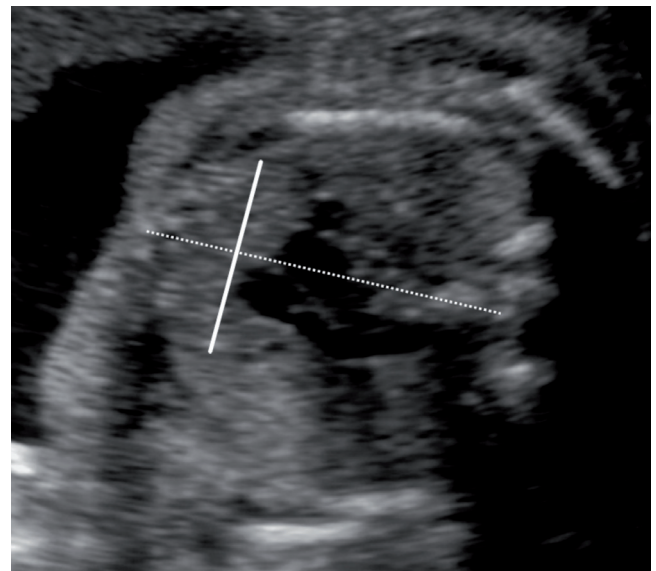


Fig. 1. Ultrasound image of the transverse diameter of the fetal thymus with a connecting line between the sternum and the spine.

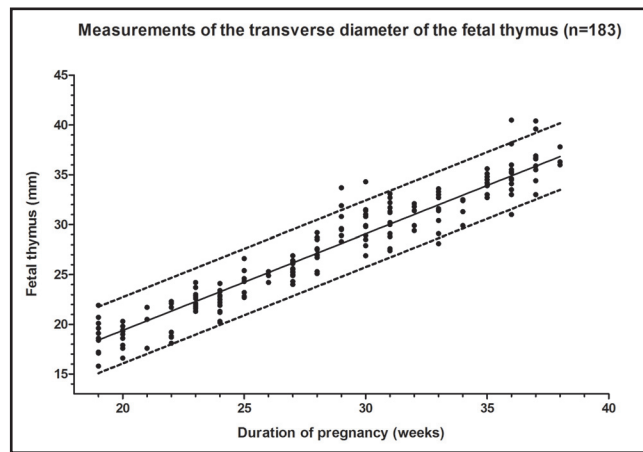


Fig. 2. Scatter plot of the fetal thymus transverse diameter in relation to gestational age (weeks). The lines represent the regression line with the 5th and 95th percentile.

Tab. 1. Linear regression equations for normalizing the transverse diameter of the fetal thymus (mm).

Variable	Regression equation	r ²	p-value
Gestational age – weeks	1.001 × week – 0.932	0.91	< 0.0001
Gestational age – days	0.143 × day – 1.34	0.92	< 0.0001

Tab. 2. Predicted mean and 5th and 95th percentile (mm) range for the transverse diameter of the fetal thymus at each gestational age.

Weeks of gestation	n	Mean	5 th percentile	95 th percentile
19	10	18.1	16.0	20.2
20	10	19.1	16.9	21.3
21	3	20.1	17.9	22.3
22	7	21.1	18.8	23.4
23	15	22.1	19.8	24.4
24	15	23.1	20.7	25.5
25	7	24.1	21.7	26.5
26	3	25.1	22.6	27.6
27	15	26.1	23.6	28.6
28	10	27.1	24.6	29.6
29	8	28.1	25.5	30.7
30	13	29.1	26.5	31.7
31	13	30.1	27.4	32.8
32	5	31.1	28.4	33.8
33	11	32.1	29.3	34.9
34	5	33.1	30.3	35.9
35	8	34.1	31.3	37.0
36	13	35.1	32.2	38.0
37	9	36.1	33.2	39.1
38	3	37.1	34.1	40.1

tation are presented in Table 1. The relationships are shown graphically in Figures 2 and 3, which illustrate the regression line, the 5th and 95th percentile with the measured data. The Spearman correlation coefficient $r=0.96$ was found to be highly statistically significant $p<0.0001$. Table 2 displays the calculated mean of the transverse diameter of the fetal thymus and the 5th and 95th percentile for gestational age between 19 and 38 weeks of gestation. A Bland-Altman plot of the intraobserver agreement for the transverse diameter of the fetal thymus is shown in Figure 4. Intraobserver variability in our study was 3.5%

DISCUSSION

The main goal of our study was to determine the transverse diameter of the fetal thymus in uncomplicated singleton pregnancy, with a secondary aim to determine the opportunity to be measured routinely during the prenatal fetal ultrasound examination in the second and the third trimester of the pregnancy. These questions are very important because they could perform the right way for our future an ultrasound clinical examination of prenatal fetal thymic involution in pathological singleton pregnancies.

Three different approaches for ultrasound measurement of fetal thymus have been published so far: the anterior-posterior thickness, the perimeter and the transverse diameter. The measurement of the anterior-posterior thickness of fetal thymus was referred to first (Felker *et al.* 1989). This technique does not appear to be useful because it suffers from a key limitation due to asymmetric shape and position of the thymus which is defined by the size and arrangement of the great heart vessels (Cho *et al.* 2007; Zalel *et al.* 2002). Other authors (Cromi *et al.* 2009; Di Naro *et al.* 2006; El-Haieg *et al.* 2008; Yinon *et al.* 2007; Zalel *et al.* 2002) have reported measurement of the thymus perimeter, but only a few studies were published about measurement of the thymic transverse diameter (De Leon-Luis *et al.* 2009; Gamez *et al.* 2010; Cho *et al.* 2007). The perimeter of the thymus is difficult to define due to poor echogenic conditions and the measurement itself is rather time consuming. On the other hand, the transverse diameter of the fetal thymus can be defined more consistently, and is therefore more readily measurable, owing to the fact that the borderline between the thymus and the lung (lateral margin of the thymus) are clearly defined (Cho *et al.* 2007; Kacerovsky & Boudys 2009).

To obtain reliable results in our study, we did not perform the measurements if the image was not of good quality due to unfavorable fetal position or maternal acoustic conditions. In 8% of fetuses the image quality was considered as unsatisfactory. Nevertheless, most of the unsuccessful measurements in our cohort of subjects were at the beginning of the study. Therefore, the failure of the fetal thymus measurement is considered to decrease with examiner experience.

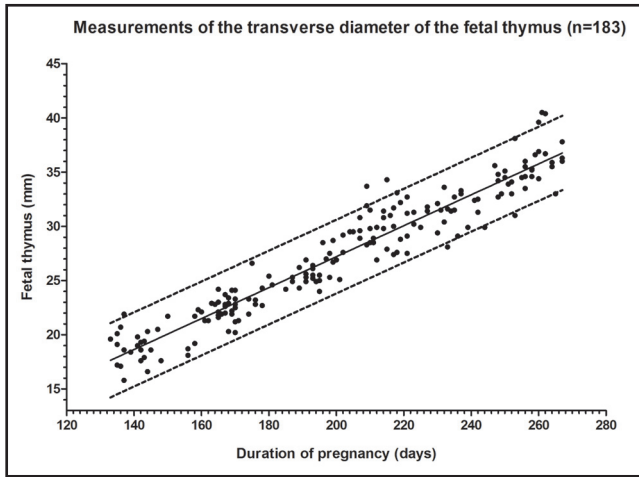


Fig. 3. Scatter plot of the fetal thymus transverse diameter in relation to gestational age (days). The lines represent the regression line with the 5th and 95th percentile.

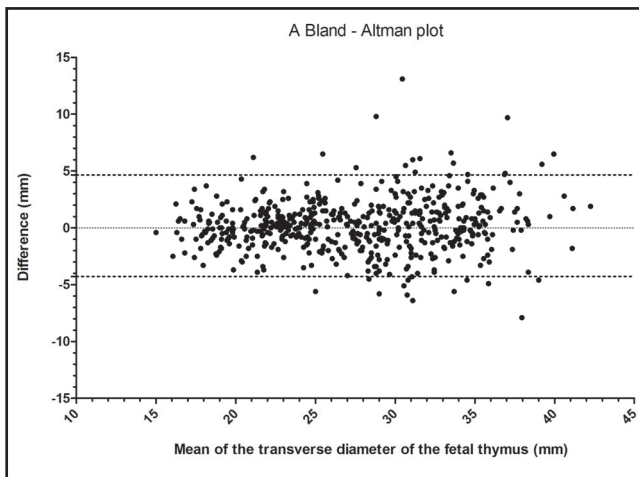


Fig. 4. Bland-Altman plot for the intraobserver agreement of measurement of the transverse diameter of the fetal thymus. The differences are plotted against mean value for each observation. The lines represent the mean with the 5th and 95th percentile.

Our finding regarding the sonographic changes in the fetal thymic transverse diameter during the second and the third trimester of uncomplicated singleton pregnancy are approximately in concordance with those previously reported (Gamez *et al.* 2010; Cho *et al.* 2007). Our values between 18 and 28 weeks of gestation are slightly higher compared to Cho's and Gomez's data. However, our predicted means between 29 and 34 weeks of gestation are in concordance with Cho's data and between 35 and 38 weeks of gestation are exactly between Cho's and Gomez's values. These comparisons are shown in Table 3.

Our nomogram was created from healthy singleton pregnancies. Interestingly, a recent study reported that the thymic transverse diameter is similar in both

Tab. 3. The comparison between published (Cho *et al.* 2007; Gamez *et al.* 2010) and our nomogram for the fetal thymic diameter by completed weeks of gestation.

Gestational age (weeks)	Cho's nomogram	Gamez's nomogram	Our nomogram
19	12	14	18
20	14	15	19
21	15	16	20
22	16	18	21
23	18	19	22
24	19	20	23
25	21	21	24
26	22	22	25
27	24	23	26
28	25	24	27
29	27	25	28
30	28	26	29
31	30	27	30
32	31	28	31
33	33	29	32
34	34	30	33
35	36	31	34
39	37	32	35
37	39	33	36
38	40	34	37

uncomplicated singleton and twin pregnancies and in addition it is not affected by twin chorionicity (Gamez *et al.* 2010). Therefore, we suppose, that our nomogram may be used not only for singleton but also for twin pregnancies.

In summary, the present study provides a normative data for the noninvasive ultrasound measurement of the transverse diameter of the fetal thymus in healthy singleton pregnancies and confirms that the fetal thymic transverse diameter can be easily measured prenatally. Nevertheless, further studies are necessary to clarify usefulness of this nomogram for detection of thymic involution in the pathological pregnancies.

ACKNOWLEDGEMENTS

This work was supported by grant from Czech Science Foundation (No. 304-09-0494).

Disclosure of interest

There is no direct or indirect commercial or financial incentive associated with publishing this article.

Details of ethics approval

The study was approved by the Institutional Review Board Committee (March 19, 2008; No. 200804 SO1P)

REFERENCES

- 1 Ciofani M, Zuniga-Pflucker JC (2007). The thymus as an inductive site for T lymphopoiesis. *Annu Rev Cell Dev Biol.* **23**: 463–493.
- 2 Cromi A, Ghezzi F, Raffaelli R, Bergamini V, Siesto G, Bolis P (2009). Ultrasonographic measurement of thymus size in IUGR fetuses: a marker of the fetal immunoendocrine response to malnutrition. *Ultrasound Obstet Gynecol.* **33**: 421–426.
- 3 De Felice C, Toti P, Santopietro R, Stumpo M, Pecciarini L, Bagnoli F (1999). Small thymus in very low birth weight infants born to mothers with subclinical chorioamnionitis. *J Pediatr.* **135**: 384–386.
- 4 De Leon-Luis J, Gamez F, Pintado P, Antolin E, Perez R, Ortiz-Quintana L, *et al.* (2009). Sonographic measurements of the thymus in male and female fetuses. *J Ultrasound Med.* **28**: 43–48.
- 5 Di Naro E, Cromi A, Ghezzi F, Raio L, Uccella S, D'Addario V, *et al.* (2006). Fetal thymic involution: a sonographic marker of the fetal inflammatory response syndrome. *Am J Obstet Gynecol.* **194**: 153–159.
- 6 El-Haieg DO, Zidan AA, El-Nemr MM (2008). The relationship between sonographic fetal thymus size and the components of the systemic fetal inflammatory response syndrome in women with preterm prelabour rupture of membranes. *BJOG.* **115**: 836–841.
- 7 Felker RE, Cartier MS, Emerson DS, Brown DL (1989). Ultrasound of the fetal thymus. *J Ultrasound Med.* **8**: 669–673.
- 8 Gamez F, De Leon-Luis J, Pintado P, Perez R, Robinson JN, Antolin E, *et al.* (2010). A study to determine the size of the fetal thymus in uncomplicated twin and singleton pregnancies. *Ultrasound Obstet Gynecol.* 10.1002/uog7578
- 9 Haynes BF, Heinly CS (1995). Early human T cell development: analysis of the human thymus at the time of initial entry of hematopoietic stem cells into the fetal thymic microenvironment. *J Exp Med.* **181**: 1445–1458.
- 10 Cho JY, Min JY, Lee YH, McCrindle B, Hornberger LK, Yoo SJ (2007). Diameter of the normal fetal thymus on ultrasound. *Ultrasound Obstet Gynecol.* **29**: 634–638.
- 11 Jeppesen DL, Hasselbalch H, Nielsen SD, Sorensen TU, Ersboll AK, Valerius NH, *et al.* (2003). Thymic size in preterm neonates: a sonographic study. *Acta Paediatr.* **92**: 817–822.
- 12 Kacerovsky M, Boudys L (2009). Re: The relationship between sonographic fetal thymus size and the components of the systemic fetal inflammatory response syndrome in women with preterm prelabour rupture of membranes. *BJOG.* **116**: 461; author reply 461–462.
- 13 Kendall MD, Yaffe P, Yoffey JM (1985). The mouse thymus in hypoxia and rebound: A histological study. *J Anat.* **142**: 85–102.
- 14 Suster S, Rosai J (1990). Histology of the normal thymus. *Am J Surg Pathol.* **14**: 284–303.
- 15 Tosi P, Kraft R, Luzi P, Cintorino M, Fankhauser G, Hess MW, *et al.* (1982). Involution patterns of the human thymus. I Size of the cortical area as a function of age. *Clin Exp Immunol.* **47**: 497–504.
- 16 Toti P, De Felice C, Stumpo M, Schurfeld K, Di Leo L, Vatti R, *et al.* (2000). Acute thymic involution in fetuses and neonates with chorioamnionitis. *Hum Pathol.* **31**: 1121–1128.
- 17 Yinon Y, Zalel Y, Weisz B, Mazaki-Tovi S, Sivan E, Schiff E, *et al.* (2007). Fetal thymus size as a predictor of chorioamnionitis in women with preterm premature rupture of membranes. *Ultrasound Obstet Gynecol.* **29**: 639–643.
- 18 Zalel Y, Gamzu R, Mashiach S, Achiron R (2002). The development of the fetal thymus: an in utero sonographic evaluation. *Prenat Diagn.* **22**: 114–117.