

# The occurrence of thyroid focal lesions and a need for fine needle aspiration biopsy in patients with acromegaly due to an increased risk of thyroid cancer

Marek RUCHALA<sup>1</sup>, Agnieszka SKIBA<sup>1</sup>, Edyta GURGUL<sup>1</sup>, Pawel URUSKI<sup>2</sup>,  
Ryszard WASKO<sup>1</sup>, Jerzy SOWINSKI<sup>1</sup>

1. Department of Endocrinology, Metabolism and Internal Medicine;
  2. Department of Hypertension, Angiology and Internal Medicine;
- Poznań University of Medical Sciences, Poznań, Poland

*Correspondence to:* Marek Ruchala, M.D. Ph.D. Associate professor  
60-355 Poznań, ul. Przybyszewskiego 49, Department of Endocrinology,  
Metabolism and Internal Medicine, Poznań University of Medical Sciences,  
Poznań, Poland.  
TEL. +48 61 867-55-14 (869-13-30); FAX: +48 61 869-1682;  
E-MAIL: mruchala@ump.edu.pl

*Submitted:* 2009-05-26    *Accepted:* 2009-06-20    *Published online:* 2009-09-02

*Key words:*                    **acromegaly; IGF-1; goiter; thyroid nodules; thyroid cancer; fine needle aspiration biopsy**

Neuroendocrinol Lett 2009; 30(3): 382-386    PMID: 19855364    NEL300309A09    © 2009 Neuroendocrinology Letters • [www.nel.edu](http://www.nel.edu)

## Abstract

**OBJECTIVE:** The high prevalence of goiter in acromegalic patients is well known. Several studies revealed increased frequency of thyroid carcinoma in these patients. The aim of the study was to evaluate the incidence of thyroid lesions, including thyroid cancer in acromegalic patients and to estimate possible factors influencing their occurrence, especially high IGF-1 level.

**MATERIALS AND METHODS:** 86 consecutive patients with acromegaly were retrospectively analyzed. 45 patients had been previously treated for acromegaly and 41 were newly diagnosed. In all subjects hGH, IGF-1, TSH, FT4 levels were determined. Thyroid gland was evaluated in ultrasound examination. Fine needle aspiration biopsy (FNAB) was performed in every solid or mixed thyroid nodule.

**RESULTS:** Thyroid morphology abnormalities were found in 75 patients (87.2%). 10 patients (11.6%) had diffuse goiter and 65 patients (75.6%) had nodular goiter. There were 5 cases of thyroid carcinoma (5.8%): 3 papillary carcinomas and two follicular variants of papillary cancer. Out of five cancers three were multifocal, one infiltrated thyroid capsule and one was diagnosed at the stage of metastases to four lymph nodes.

**CONCLUSIONS:** Our study confirmed common co-existence of acromegaly and thyroid lesions. Furthermore, it revealed considerably high occurrence of thyroid carcinoma in these patients. In view of this correlation, the potential role of IGF-1 in pathogenesis of benign and malignant thyroid neoplasms should be considered. Due to high frequency of thyroid cancer in acromegalic patients, we suggest to perform fine needle aspiration biopsy in each case of thyroid nodule.

**Abbreviations:**

aTPO	– anti-thyroid peroxidase antibody
DTC	– differentiated thyroid carcinoma
FNAB	– fine needle aspiration biopsy
FT4	– free thyroxine
hGH	– human growth hormone
IGF	– insulin-like growth factor
IGFBP	– insulin-like growth factor binding protein
MRI	– magnetic resonance imaging
OGTT	– oral glucose tolerance test
TNM classification	– tumor, lymph nodes, metastasis classification
TRAb	– thyroid-stimulating hormone (TSH)-receptor antibodies
TSH	– thyroid-stimulating hormone

**INTRODUCTION**

Acromegaly is a disease caused by increased pituitary growth hormone (hGH) secretion, that occurs after the closure of epiphyses. The growth promoting effect of hGH is mainly mediated by insulin-like growth factor 1 (IGF-1), that binds IGF-1 receptors present on cell membranes.

The clinical features of acromegaly are connected with bony and soft tissue overgrowth. However, neoplasms may be one of the complications. Diffuse and nodular goiter in acromegalic patients are common (Gunay *et al.* 2003, Wuster *et al.* 1991). The risk of developing thyroid cancers is also greater than in general population (Gasperi *et al.* 2002, Tita *et al.* 2005).

Frequent co-existence of thyroid lesions with acromegaly suggests an important role of elevated hGH and IGF-1 levels in their pathogenesis. Insulin-like growth factors are essential regulators of cell proliferation, differentiation, transformation and apoptosis. Recently, they have been suspected of being responsible for cancer progression and malignant cell protection from apoptosis (Baserga 1995, Humbel 1990, Isozaki *et al.* 1987, Jenkins & Bustin 2004, Lewiński & Wojciechowska 2007, Macaulay 1992, Wasko *et al.* 2005, Völzke *et al.* 2007)

The aim of our study was to evaluate the frequency of benign and malignant thyroid lesions in acromegalic patients and to estimate possible factors influencing their prevalence, including duration of disease, therapeutic methods and hormonal levels, IGF-1 especially.

**MATERIAL AND METHODS**

86 consecutive patients with acromegaly were retrospectively analyzed. There were 52 women and 34 men, aged from 24 to 83 (mean age  $49,9 \pm 11,1$ ) admitted to Department of Endocrinology in the period of 2001–2005. All patients came from area with mild iodine deficiency.

Diagnosis of acromegaly was based on clinical signs, increased hGH levels, lack of hGH suppression below 1 ng/ml after a standard oral glucose tolerance test (OGTT) and IGF-1 levels over normal values for age and gender. The source of hGH excess was found by

magnetic resonance imaging (MRI). Duration of acromegaly was estimated from the clinical history.

45 patients had been previously treated for acromegaly and 41 were newly diagnosed. 20 had been treated only by surgery, 13 had been treated only by radiotherapy, 13 by both surgery and radiotherapy. At the time of the study 72 patients had active disease (40 –untreated, 32 – under treatment with somatostatin analogues) and 14 were in remission.

Biochemical and immunological investigation included measurements of serum hGH, IGF-1, free T4 (FT4) and TSH in every patient. Serum free T4 concentration and TSH level were measured by electrochemiluminescence immunoassay (ECLIA) with Modular Analytics E170 system (Roche Diagnostic, Germany). Serum hGH concentration was measured by IRMA (BioSource Europe S.A., Nivelles, Belgium), with a sensitivity of 0,066 ng/ml. Serum IGF-1 was determined by radioimmunoassay RIA-CT (BioSource Europe S.A, Nivelles, Belgium), with a sensitivity of 3.4 ng/ml. Anti-thyroid peroxidase antibody (aTPO) and thyroid-stimulating hormone (TSH)-receptor antibodies (TRAb) were measured when Hashimoto thyroiditis or Graves' disease were suspected.

Thyroid was evaluated in ultrasound examination (Aloka SSD 1100) with a 7.5 MHz linear transducer (Tokyo, Japan). Thyroid volume was calculated with the ellipsoid formula: width [cm] x length [cm] x thickness [cm] x  $\pi/6$  for each lobe. Goiter was defined when the thyroid volume exceeded 18ml in females and 25ml in males. Presence of thyroid nodule(s) defined nodular goiter.

Fine needle aspiration biopsy (FNAB) was performed in every solid or mixed thyroid nodule. All biopsy and thyroidectomy specimens were respectively cytologically and histologically reviewed.

Thyroid cancers were staged according to tumor, lymph node, distant metastasis (TNM) classification. All patients with cancer after total thyroidectomy were referred to routine follow-up procedures for DTC (differentiated thyroid carcinoma).

The control group consisted of 92 participants from area with mild iodine deficiency, matched for age and gender to the study group. It reflected the prevalence of thyroid disorders in general population.

The incidence of both diffuse and nodular goiter in acromegalic patients in comparison to the study group was analyzed with Chi2, Yates correction test. One-sided exact Fisher's test was used to evaluate the prevalence of thyroid cancer and to compare the occurrence of nodular goiter between the first and the second study groups.

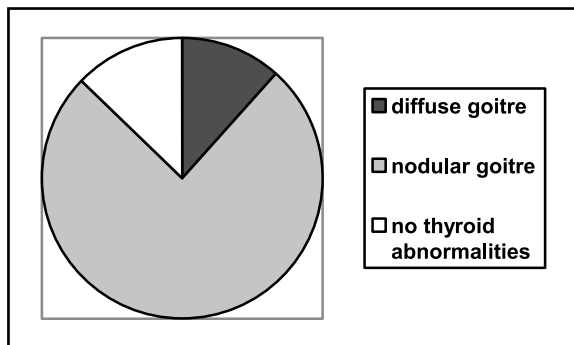


Fig.1. Thyroid abnormalities in the study group.

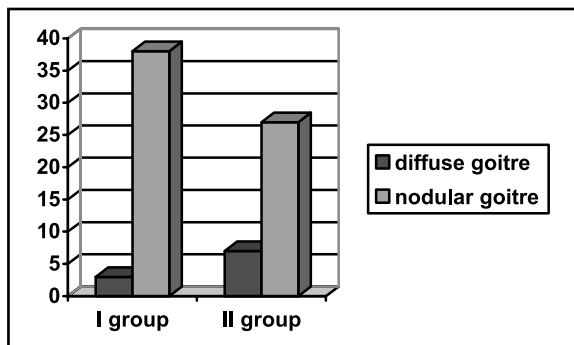


Fig.2. Prevalence of diffuse and nodular goitre according to the duration of acromegaly.

## RESULTS

Thyroid morphology abnormalities were found in 75 patients (87.2%), considerably more than in the control group ( $p < 0.001$ ). 10 patients (11.6%) had diffuse goitre (volume 18.14 – 49.74ml, mean 31.8ml) and 65 patients (75.6%) had nodular goitre (volume 1.27–135.3ml, mean 40.2ml) (Fig. 1).

The patients were divided into two groups. The first group included 45 patients with disease duration of over five years; the second group included 41 subjects with disease duration of less than five years. In the first group diffuse and nodular goitre was diagnosed in 3 and 38 patients (6.7% and 84.4%) respectively. In the second group diffuse and nodular goitre was diagnosed in 7 and 27 patients (17% and 65.9%) respectively (Fig. 2). The incidence of nodular goitre was higher in patients with acromegaly duration of more than 5 years ( $p = 0.9$ ).

16 patients underwent total or subtotal thyroidectomy. The reasons for thyroid surgery were a large goiter (volume > 50ml) or suspicious clinical (and/or ultrasound features) in five patients, nodulus follicularis in two patients, nodulus oxyphilicus in two patients, nodulus hyperplasticus in four patients and carcinoma papillare in three patients.

Among sixteen operated patients histological examination revealed five well-differentiated papillary thy-

roid carcinomas ( $p = 0.02$  in comparison to the control group). Two of these were follicular variants.

Three thyroid cancers had been detected by FNAB before surgery, and two were discovered at histological examination after subtotal thyroidectomy for large goiter. The latter were re-operated for total thyroidectomy.

There were four women and one man among acromegalic patients with DTC. The mean age was 48.2 with a range of 45–52. At the time of diagnosis acromegaly was active in three patients with estimated duration of the disease 12 to 20 years. One thyroid carcinoma had been revealed before acromegaly was diagnosed.

Out of five cancers revealed in the study three were multifocal and two were solitary lesions (one microcarcinoma with diameter < 10mm).

## DISCUSSION

The high prevalence of diffuse and nodular goiter in acromegalic patients has been widely proven (Kasagi *et al.* 1999, Wuster *et al.* 1991). In our study the frequency of thyroid morphology abnormalities was also increased in comparison with general population. It was slightly higher in patients with the duration of acromegaly of over 5 years. The percentage of nodular goiter in our study was also higher in this group (84.4%).

The pathogenesis of thyroid nodule formation in acromegaly has not been explained. Undoubtedly, the risk of thyroid lesions development depends on the duration of acromegaly. Persistently elevated IGF-1 level correlates with thyroid volume and predisposes to thyroid nodule formation (Gasperi *et al.* 2002, Junik *et al.* 1997). Furthermore, previous studies have demonstrated that benign and malignant thyroid tumors tend to escape from the requirement for exogenous source of IGF-1 and begin its autocrine production (Williams *et al.* 1989, Yashiro *et al.* 1994). The concentration of IGF-1 in thyroid nodules has been shown much higher than in normal thyroid tissue, what supports the IGF-1 dependent theory (Minuto *et al.* 1989).

There are reports charging an increased amount of connective tissue and excessive collagen synthesis in thyroids of acromegalic patients. They assume that thyroid follicles are squeezed into the meshwork of connective tissue and form a nodular growth pattern (Ramelli *et al.* 1982, Verde *et al.* 1986).

In comparison to previous researches, our study revealed considerably high frequency of thyroid carcinoma (5.8% of examined subjects) (Tab. 1). There were three papillary carcinomas and two follicular variants of papillary cancers. Although the prognosis for differentiated thyroid carcinomas is usually favourable, these five cancers revealed features of particular aggression. Three of them were multifocal, one infiltrated thyroid capsule and one was diagnosed at the stage of metastases to four lymph nodes.

The pathogenesis of thyroid carcinoma in acromegaly is still unclear. Possibly elevated hGH and IGF-1 levels cause nodular goiter, which then undergoes malignant transformation (Franceschi *et al.* 1999, From *et al.* 2000). An important carcinogenic role of IGF-1 has been highlighted since previous researches reported, that apart from autocrine and paracrine production thyroid cancers have significantly more IGF-1 binding sites (IGF-1 receptors) (Vella *et al.* 2007).

Growth hormone stimulates the secretion of IGF-1. However, hGH also induces the production of IGF-binding protein 3 (IGFBP 3), which binds 70–80% of circulating IGF-1 and inhibits cellular growth (Wolk 2004). Thus, peripheral tissues are exposed to both growth promoting and growth inhibiting factors. These opposite consequences have interested scientists for a long time. It has been proved, that high level of IGF-1 correlates positively with increased risk of colon cancer, prostate cancer and premenopausal breast cancer (Chan *et al.* 1998, Cullen *et al.* 1990, Matyja *et al.* 2006, Popovic *et al.* 1998). In our study two subjects with thyroid carcinoma suffered also from breast cancer.

The influence of IGFBP3 on carcinogenesis is still discussed. On the one hand, in acromegaly the concentration of this protein is low, what increases the active pool of mitogenic IGF-1. On the other hand, studies demonstrated that elevated IGFBP 3 level correlates positively with greater risk of premenopausal breast cancer (Renehan *et al.* 2004)

Discussing the priority of hGH-dependent mechanism in pathogenesis of thyroid cancers, we must admit, that there are theories supporting the role of TSH. Studies performed on the FRTL-5 rat thyroid cell line demonstrated that IGF-1 alone is not able to induce a notable increase in cell number. Together with TSH the effect is much more significant (Isozaki *et al.* 1987, Takahashi *et al.* 1990). The progression through the cell cycle stimulated by IGF-1 was also minimal, unless TSH induced cell competence (Cheung *et al.* 1996). However, on the other hand, researches carried out on thyroid cell cultures showed, that the mitogenic effects of TSH alone are hardly unnoticed and they are greatly potentiated by IGF-1 (Dumont *et al.* 1992, Milazzo *et al.* 1992, Roger *et al.* 1988). Most of the patients examined in our study had TSH levels either low or within normal range. Thus, elevated hGH and IGF-1 concentrations appear to emerge as the key factors of thyroid morphology disorders

There are many other factors, which may induce carcinogenesis. One of the therapeutic methods in acromegaly is radiotherapy. Two of examined subjects were exposed to ionized radiation. We must take into account the fact, that it could also induce or fasten the development of thyroid morphology abnormalities.

The mechanisms underlying frequent benign and malignant tumors in acromegaly are complex. However, in view of this correlation, the potential role of IGF-1 in their pathogenesis should be considered.

**Tab. 1** Acromegaly and thyroid cancer

AUTHOR	YEAR	NUMBER OF SUBJECTS	NUMBER OF THYROID CANCERS	%
Barzilay <i>et al.</i> <sup>2</sup>	1991	87	2	2.3
Ron <i>et al.</i> <sup>29</sup>	1991	1041	1	0.1
Cheung <i>et al.</i> <sup>6</sup>	1997	50	0	0
Orme <i>et al.</i> <sup>25</sup>	1998	1239	1	0.08
Popovic <i>et al.</i> <sup>26</sup>	1998	220	3	1.36
Higuchi <i>et al.</i> <sup>14</sup>	2000	44	2	4.5
Baris <i>et al.</i> <sup>1</sup>	2002	1634	3	0.18
Gasperi <i>et al.</i> <sup>11</sup>	2002	258	3	1.2
Hermann <i>et al.</i> <sup>13</sup>	2004	73	4	5.5
Tita <i>et al.</i> <sup>32</sup>	2005	125	7	5.6

## Conclusions

Our study confirmed that diffuse and nodular goiters are common in acromegalic patients. Furthermore, it also revealed considerably high occurrence of thyroid carcinoma. Thus, we suggest, that fine needle aspiration biopsy should be performed in each case of thyroid nodule in acromegalic patients.

## REFERENCES

- 1 Baris D, Gridley G, Ron E, Weiderpass E, Mellekjaer L, Ekblom A, *et al.* (2002), Acromegaly and cancer risk: a cohort study in Sweden and Denmark, *Cancer Causes Control*, **13**: 395–400.
- 2 Barzilay J, Heatly GJ, Cushing GW (1991), Benign and malignant tumors in patients with acromegaly, *Arch Intern Med*, **151**: 1629–1632.
- 3 Baserga R (1995), The insulin-like growth factor I receptor: a key to tumor growth?, *Cancer Res*, **55**: 249–252.
- 4 Chan JM, Stampfer MJ, Giovannucci E, Gann PH, Ma J, Wilkinson P *et al.* (1998), Plasma insulin-like growth factor I and prostate cancer risk: a prospective study, *Science*, **279**: 563–566.
- 5 Cheung NW, Lou JC, Boyages SC (1996), Growth hormone does not increase thyroid size in the absence of thyrotropin, a study in adults with hypopituitarism, *J Clin Endocrinol Metab*, **81**(3): 1179–1183.
- 6 Cheung NW, Boyages SC (1997) Increased incidence of neoplasia in females with acromegaly, *Clin Endocrinol (Oxf)*, **47**: 323–327.
- 7 Cullen KJ, Yee D, Sly WS, Perdue J, Hampton B, Lippman ME *et al.* (1990), Insulin-like growth factor receptor expression and function in human breast cancer, *Cancer Res*, **50**: 48–53.

- 8 Dumont JE, Lamy F, Roger P, Maenhaut C (1992), Physiological and pathological regulation of thyroid cell proliferation and differentiation by thyrotropin and other factors, *Physiol Rev*, **72**: 667–697.
- 9 Franceschi S, Preston-Martin S, Dal MAso L, Negri E, La Vecchia C, Mack WJ *et al* (1999), A pooled analysis of case-control studies of thyroid cancer, Benign thyroid diseases. *Cancer Causes Control*, **10**: 583–595.
- 10 From G, Mellemgaard A, Knudsen N, Jorgensen T, Perrild H (2000), Review of thyroid cancer cases among patients with previous benign thyroid disorders, *Thyroid*, **10**: 697–700.
- 11 Gasperi M, Martino E, Manetti I, Arosio M, Porretti S, Faglia G *et al* (2002), Acromegaly Study Group of the Italian Society of Endocrinology. Prevalence of thyroid diseases in patients with acromegaly: results of an Italian multi-center study, *J Endocrinol Invest*, **25**: 240–245.
- 12 Gunay E, Ope A, Cicek C, Yukselen V (2003), Follicular thyroid carcinoma in a patient with acromegaly, *Turkish Journal of Endocrinology and Metabolism*, **1**: 45–47.
- 13 Hermann BL, Baumann H, Janssen OE, Görges R, Schmid KW, Mann K (2004), Impact of disease activity on thyroid diseases in patients with acromegaly: Basal evaluation and follow-up, *Exp Clin Endocrinol Diabetes*, **112**: 225–230.
- 14 Higuchi Y, Saeki N, Iuchi T, Uchino Y, Tatsuno I, Uchida D *et al* (2000), Incidence of malignant tumors in patients with acromegaly, *Endocr J*, **47** (Suppl): 57–60.
- 15 Humbel RE (1990), Insulin-like growth factors 1 and 2, *Eur J Biochem*, **190**: 445–462.
- 16 Isozaki O, Santisteban I, Chan J, Grollman E, Kohn L (1987), Insulin and insulin-like growth factor-I (IGF-I) regulate differentiation as well as growth in FRTL 5 cells, *Acta Endocrinol (Copenh)*, **281**(Suppl): 288–292.
- 17 Jenkins PJ, Bustin SA (2004), Evidence for a link between IGF-I and cancer, *Eur J Endocrinol*, **151**: 17–22.
- 18 Junik R, Sawicka J, Kozak W, Gembicki M (1997), Thyroid volume and function in patients with acromegaly living in iodine deficient areas, *J Endocrinol Invest*, **20**: 134–137.
- 19 Kasagi K, Shimatsu A, Miyamoto S, Misaki T, Sakahara H, Konishi J (1999) Goiter associated with acromegaly: sonographic and scintigraphic findings of the thyroid gland, *Thyroid*, **9**(8): 791–796.
- 20 Lewiński A, Wojciechowska K (2007), Genetic background of carcinogenesis in the thyroid gland, *Neuroendocrinol Lett*, **28**(2): 77–105.
- 21 Macaulay VM (1992). Insulin-like growth factors and cancer, *Br J Cancer*, **65**: 311–320.
- 22 Matyja V, Kos-Kudła B, Foltyn W, Strzelczyk J, Latos W, Marek B *et al* (2006), Detection of colorectal lesions by using autofluorescence colonoscopy in acromegalics and their relation to serum growth hormone and insulin-like growth factor-1 levels: *Neuroendocrinol Lett*, **27**(5): 639–643.
- 23 Milazzo G, La Rosa GL, Catalfamo R, Vigneri R, Belfiore A (1992), Effect of TSH in human thyroid cells. Evidence for both mitogenic and antimitogenic effects, *J Cell Biochem* **49**: 231–238.
- 24 Minuto F, Barreca A, Del Monte P, Cariola G, Torre GC, Guiordano G (1989), Immunoreactive insulin-like growth factor (IGF) 1 and IGF-1 binding protein content in human thyroid tissue. *J Clin Endocrinol Metab* **68**: 621–626.
- 25 Orme SM, McNally RJ, Cartwright RA, Belchetz PE (1998), Mortality and cancer incidence in acromegaly: a retrospective cohort study, United Kingdom Acromegaly Study group, *J Clin Endocrinol Metab*, **83**: 2730–2734.
- 26 Popovic V, Damjanovic S, Micic D, Nesovic M, Djurovic M, Petakov M *et al* (1998) Increased incidence of neoplasia in patients with pituitary adenomas, *Clin Endocrinol*, **49** (4): 441–445.
- 27 Ramelli F, Studer H, Bruggisser D (1982), Pathogenesis of thyroid nodules in multinodular goiter, *Am J Pathol*, **109**: 215.
- 28 Renehan AG, Zwahlen M, Minder C, O'Dwyer ST, Shalet SM, Egger M (2004), Insulin like growth factor (IGF) I, IGF binding protein – 3 and cancer risk: systematic review and meta-regression analysis, *Lancet*, **363**: 1346–1353.
- 29 Ron E, Gridley G, Hrubec Z, Page W, Arora S, Fraumeni JF Jr (1991) Acromegaly and gastrointestinal cancer, *Cancer*, **68**: 1673–1677.
- 30 Roger P, Taton M, Van sande J, Dumont J (1988), Mitogenic effects of thyrotropin and adenosine 3'5'-monophosphate in differentiated normal human thyroid cells in vitro, *J Clin Endocrinol Metab*, **66**: 1158–1165.
- 31 Takahashi S, Conti M, Van Wyk JJ (1990) Thyrotropin potentiation of insulin-like growth factor-I dependent deoxyribonucleic acid synthesis in FRTL5 cells: mediation by an autocrine amplification factor(s), *Endocrinology*, **126**: 736–745.
- 32 Tita P, Ambrosio MR, Scollo C, Carta A, Gangemi P, Bondanelli M, *et al* (2005) High prevalence of differentiated thyroid carcinoma in acromegaly, *Clin Endocrinol (Oxf)* **63**(2): 161–167.
- 33 Wasko R, Michalek K, Pacholska J, Obrepalska-Stepiowska, Gozdzicka-Jozefiak A, Sowiński J (2005), Clinical significance of the insulin-like growth factor 1 gene promoter (P1) polymorphism in thyroid nodular disease, *Neuroendocrinol Lett*, **26**: 699–703.
- 34 Williams DW, Williams ED, Wynford TD, Evidence for autocrine production of IGF-1 in human thyroid adenomas (1989), *Mol Cell Endocrinol*, **61**(1): 139–143.
- 35 Wolk A, (2004), The growth hormone and insulin-like growth factor 1 axis and cancer. *Lancet*, **363**: 1336–1337.
- 36 Wuster C, Steger G, Schmelzle A, Gottswinter J, Minne HW, Ziegler R (1991), Increased incidence of euthyroid and hyperthyroid goitres independently of thyrotropin in patients with acromegaly, *Horm Metab Res*, **23**: 131–134.
- 37 Vella V, Sciacca L, Pandini G, Mineo R, Squarrito S, Vigneri R *et al* (2001). The IGF system in thyroid cancer: new concepts. *Mol Pathol*, **54**: 121–124.
- 38 Verde GC, Santi I, Chiodini P, Cozzi R, Dallabonzana D, Oppizzi G, *et al* (1986), Serum type III procollagen propeptide levels in acromegalic patients, *J Clin Endocrinol Metab*; **63**: 1406.
- 39 Völzke H, Friedrich N, Schipf S, Haring R, Lüdemann J, Nauck M, *et al* (2007) Association between serum insulin-like growth factor-I levels and thyroid disorders in a population-based study, *J Clin Endocrinol Metab*; **92**(10): 4039–4045.
- 40 Yashiro T, Arai M, Shizume K, Obara T, Murakami H, Hizuka N, *et al* (1994) Increased activity of insulin like growth factor-binding protein in human thyroid papillary cancer tissue, *Jpn J Cancer Res* **85**(1): 46–52.