

Meigs' syndrome and virilizing ovarian fibrothecoma complicating pregnancy. A case report and review of the literature

Marek NOWAK¹, Lech PODCIECHOWSKI², Tomasz KRAWCZYK³, Jan WILCZYNSKI⁴

1. Department of Gynecologic Surgery, Polish Mother's Memorial Hospital - Research Institute;
2. Department of Maternal-Fetal Medicine and Gynecology, Polish Mother's Memorial Hospital - Research Institute; and the III Department of Obstetrics and Gynecology, Medical University;
3. Department of Clinical Patomorphology, Polish Mother's Memorial Hospital - Research Institute;
4. Professor and Chairman, Department of Maternal-Fetal Medicine and Gynecology, Polish Mother's Memorial Hospital - Research Institute; and 3rd Department of Obstetrics and Gynecology, Medical University; Lodz, Poland.

Correspondence to: Marek Nowak, M.D, Ph.D.
Department of Gynecologic Surgery, Polish Mother's Memorial Hospital - Research Institute, ul. Rzgowska 281/289, 93-338 Lodz, POLAND.
TEL. +48 42 2711543, FAX +48 42 2711221, E-MAIL: mrn@poczta.onet.pl

Submitted: 2008-09-26 Accepted: 2008-12-06 Published online: 2009-07-05

Key words: Meigs syndrome; pregnancy; ovarian tumor; virilization; hirsutism

Neuroendocrinol Lett 2009; 30(2):192-194 PMID: 19675518 NEL300209C01 © 2009 Neuroendocrinology Letters • www.nel.edu

Abstract

BACKGROUND: A half of virilizing ovarian tumors in pregnancy are malignant. The risk of cancer increases with ascites and hydrothorax. Our case shows that such tumor can be benign with good outcome. **CASE:** Primigravida in 30 weeks with advanced hirsutism (from 15 weeks), vomiting, epigastric pain, dyspnoea, ascites, hydrothorax, ovarian mass and high level of serum testosterone was operated. After the tumorectomy (fibrothecoma) we performed cesarean section (placental abruption suspected). The female fetus had no signs of virilization. In mother all symptoms and effusions resolved. **CONCLUSION:** Meigs' syndrome in pregnancy leads to acute clinical symptoms and needs the surgical intervention with the risk of placental abruption. Virilization of mother was the first symptom of ovarian tumor but the female fetus was protected of hyperandrogenism.

INTRODUCTION

Discovering of a solid ovarian tumor coexisting with ascites and hydrothorax usually leads to the diagnosis of ovarian cancer. In pregnancy such situation is highly unfavorable, but we should remember about extremely rare, but with good prognosis benign condition called Meigs' syndrome. In 1954 Meigs gave a wider definition of a syndrome termed his name including not only ovarian fibroma but all predominantly fibrous solid ovarian lesions coexisting with ascites and hydrothorax with the resolving of these symptoms

after removing of the tumor (Meigs 1954). Meigs' syndrome in pregnant women is extremely rare. We found only five such cases described in the literature (Foster 1971; Griffin 1967; Hopkins *et al.* 1986) (PubMed; 1950-May 2008; all languages; search terms: Meigs syndrome and pregnancy) – they were: fibroma and thecoma. To our knowledge, reported here case is the first one (additional search terms: ovarian tumor, virilization, hirsutism and pregnancy) when ovarian tumor not only caused Meigs' syndrome, but was also hormonally active and responsible for maternal masculinization. Moreover, hyperandrogenic changes of this

pregnant woman were the first symptoms of the ovarian tumor.

CASE

A 22-year-old primigravida was referred to our hospital with the initial diagnosis: 31 weeks gestation, threatened preterm labor, right ovarian tumor, hirsutism and suspicion of ileus. She had no history of masculinization or any other hormonal disorders before pregnancy. At the admission, the patient's blood pressure was 115/80 mm Hg, pulse 96/minute, temperature 37.2 C, weight 62 kg, and height 161 cm. Her chief complaints were: nausea, vomiting, pain in the upper part of the abdomen for the last two days and shortness of breath and irregular uterine contractions since day before admission. The clinical evaluation revealed distended, symmetrically enlarged, soft abdomen with the signs of ascites, only single, weak intestinal movements, medium pain in the epigastric region, suspicion of bilateral pleural effusions in the lower parts of lungs, thyroid gland with increased density and slightly irregular surface. Uterus was soft, enlarged to about 30 weeks, cervix was 1.5 cm long and closed, fetal heart rate and contraction stress test were normal with irregular uterine contractions present. She also presented advanced hirsutism (22 points in Ferriman-Gallway scale), facial and upper trunk acne, but the voice and external female genital organs were normal. The first signs of hyperandrogenism had appeared in about 15 week of gestation and rapidly increased in the third trimester. Taking the history of her pregnancy we discovered that the ovarian tumor was found for the first time a day before admission to our institute.

Blood tests showed elevated white blood cell count (WBC 21800 with a normal differential), C-reactive protein (CRP 8.0 mg/dL), erythrocyte sedimentation rate (ESR 39 mm/h), fibrinogen (6.2 g/L) and slightly decreased total protein level (5.5 g/dL). The other blood parameters were within normal range. Hormonal maternal blood tests revealed highly elevated testosterone (21.0 ng/mL; normal range: 0.06–0.82 ng/mL), whereas dehydroepiandrosterone sulfate (35.3 µg/mL), cortisol (18.5 µg/mL), adrenocorticotropin (19.8 pg/mL), thyroid-stimulating hormone (1.75 mIU/L), free triiodothyronine (1.6 pg/mL), free thyroxine (0.98 ng/dL), anti-thyroglobulin (25.5 IU/mL) and anti-thyroid peroxidase (11.2 IU/mL) antibodies were in normal range. Ultrasound investigation showed a normal singleton pregnancy in about 29.5 weeks, in the Douglas pouch present a solid ovarian tumor (10–11 cm in diameter) with rich, pathologic vascularization, a lot of free liquid in the abdomen and effusion in both pleural cavities (confirmed by chest radiography).

According to poor condition of the mother (subileus, dyspnoea) and "suspected" ovarian tumor with ascites and hydrothorax we decided to perform longitudinal laparotomy. We removed about 2000 mL of clear, serous fluid from the peritoneal cavity. Behind

the uterus, we found a solid yellow-grey right ovarian tumor with intact smooth capsule (size: 11 × 10 × 7 cm) wedged in the Douglas pouch, fixed with plane adhesion with the uterus and the broad ligament. According to these technical conditions we had to touch and move the pregnant uterus to release the tumor and make right ovariectomy. During waiting for the frozen section we noticed the intense contraction of the uterus which got red-blue on the anterior wall and rapid fetal movements. We suspected the beginning of placental abruption and performed cesarean section delivering the female fetus weighted 1300 grams with Apgar scores of 7 at one minute and partially abrupted placenta. Frozen section revealed benign ovarian tumor and the inspection of the abdominal cavity showed no other pathologies. The final pathologic diagnosis on paraffin-embedded sections was fibrothecoma with massive edema, with numerous luteinized cells, vessel thrombosis and haemorrhagiae (Fig. 1). Placenta was without signs of chorioamnionitis. Aerobic and anaerobic cultures of ascitic fluid were negative and there were no cancer cells on its cytology. Female newborn after the delivery had serum testosterone level 15 times lower (1.34 ng/mL) than maternal and had no signs of virilization and inherited infection; she was discharged in a good condition, weighting 2200 grams. In mother, ileus, vomiting, ascites, hydrothorax successively disappeared, body temperature and serum testosterone concentration (0.26 ng/mL) lowered to the normal range, CRP decreased to 2.7 mg/dl and WBC to 14100. She was discharged on the eight day after surgery.

COMMENT

In the presented case masculinization of the mother was the first sign of this hormonally active fibrothecoma of the right ovary. Ascites and hydrothorax gave clinical symptoms 15 weeks later and in the same time the presence of ovarian tumor was established. The result of histopathologic examination suggests that the tumor grew rapidly at the end of pregnancy (massive edema, haemorrhagiae). The review of 102 cases of virilizing ovarian tumors associated with pregnancy [2] showed that one third were luteoma, 14% Krukenberg tumors, 12% of epithelial origin, 11% sex cord stromal tumors and fifty percent of them were malignant. Thus, in our decision making process we had to consider two extremely rare situations in pregnancy: ovarian malignancy or Meigs' syndrome caused by virilizing benign ovarian tumor.

From five described before cases of Meigs' syndrome complicating pregnancy three resulted in the termination of pregnancy in the first trimester by stillbirth or hysterectomy (one mother died) (Foster 1971; Griffin 1967). The fourth case, observed by Griffin (1967) was operated in 10 weeks gestation – an ovarian fibroma twisted on its pedicle was excised and the gravid uterus left intact. Ascites and hydrothorax disappeared within several days and pregnancy progressed normally to vag-

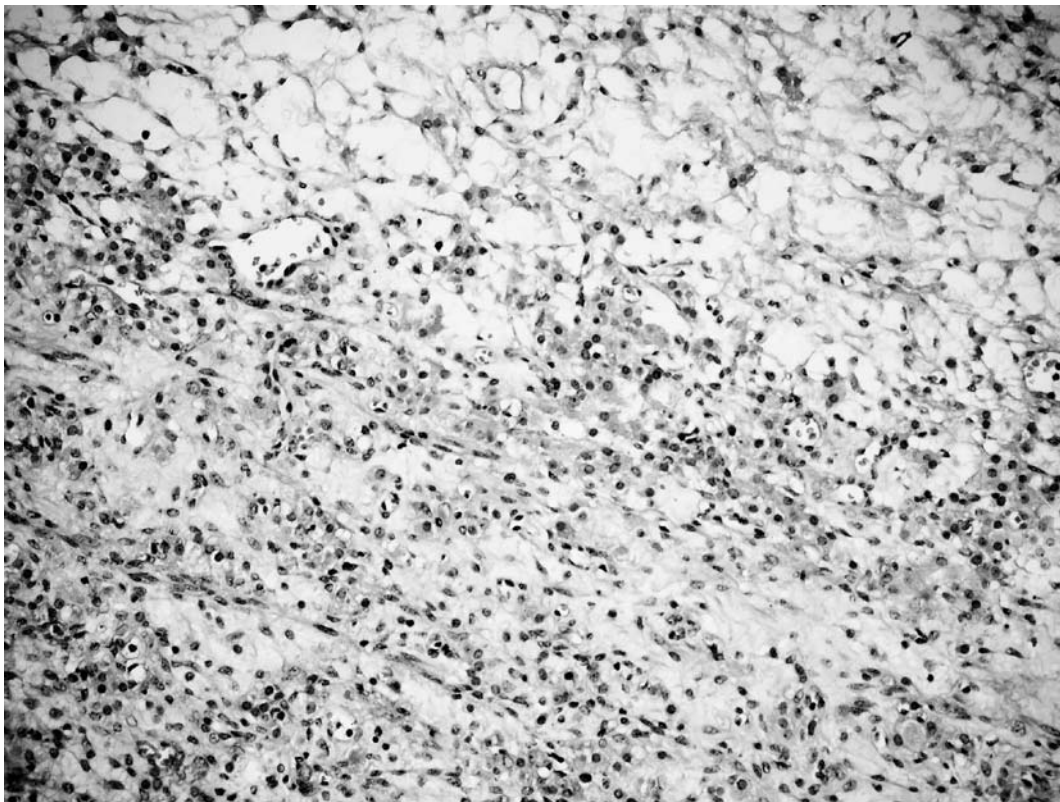


Figure 1. Fibrothecoma. Tumor cells with pale and dense cytoplasm, nuclei vary from round to spindle shaped. Some cells are vacuolated. Luteinized cells are numerous. Mitotic figures are absent (hematoxylin-eosin, x100).

inal delivery at term. The last case, reported by Hopkins *et al.* (1986) was 16-year-old primigravida in 31 weeks gestation with worsening preeclampsia. During cesarean section an 1800 gm female newborn (Apgar score of 6 at one minute) was delivered and a torsioned ovarian thecoma was excised. The pleural effusions resolved within one week (Hopkins *et al.* 1986). The outcome of our case was also quite successful but not fully expected. In case of benign ovarian lesion we wanted to make only tumorectomy and prolong pregnancy at term, but we were forced by placental abruption to make a cesarean section. The delivered female fetus had peripheral blood testosterone level within normal range and had no signs of masculinization. The data from the literature showed that 50–65% of female newborns born to virilized mothers (with luteomas) are virilized (Cohen *et al.* 1982). In our case the female fetus was rather shortly exposed to high level of testosterone and was protected probably by placental aromatization of the circulating androgens (Illingworth *et al.* 1992).

In six reported here cases of Meigs' syndrome in pregnancy, the torsion of the tumor's pedicle occurred in three patients. The risk of torsion of ovarian tumor is higher in pregnancy (rapid change of the uterine size and position) and markedly increases when the ovarian cyst is coexisting with ascites (floating of the tumor). Moreover, increasing ascites and hydrothorax led in majority of described pregnant women (5/6 cases) to persistent nausea, vomiting and dyspnoea. These com-

plications force a physician to immediate surgical intervention. Thus, after diagnosing of solid ovarian tumor with ascites and hydrothorax in pregnant woman we recommend the elective surgical treatment with the monitoring of fetus and placenta (i.e. intraoperative ultrasound). At least, tumorectomy with the frozen section of the lesion should be performed to rule out the malignancy and to avoid the tumor torsion, ileus, acute dyspnoea in the later course of pregnancy. When the tumor is benign, ascites and hydrothorax usually disappears within several days and the pregnancy can be prolonged at term.

REFERENCES

- 1 Cohen DA, Daughaday WH, Weldon VV (1982). Fetal and maternal virilization associated with pregnancy. A case report and review of the literature. *Am J Dis Child.* **136**: 353–6.
- 2 Dudley AG (1997). Ovarian tumors complicating pregnancy. In: Rock JA, Thompson JD, editors. *Te Linde's operative gynecology*. 8th ed. Philadelphia, New York: Lippincott-Raven Publishers. p. 872–85.
- 3 Foster HW (1971). Meigs syndrome complicated by pregnancy. *J Natl Med Assoc.* **63**: 372–3.
- 4 Griffin WT (1967). Meigs's syndrome and pregnancy. Case reports. *Mo Med.* **64**: 408–10.
- 5 Hopkins M, Malviya VK, Nunez C (1986). Meigs's syndrome and ovarian thecoma in pregnancy. *J Reprod Med.* **31**: 198–202.
- 6 Illingworth PJ, Johnstone FD, Steel J, Seth J (1992). Luteoma of pregnancy: masculinisation of a female fetus prevented by placental aromatization. *Br J Obstet Gynaecol.* **99**: 1019–20.
- 7 Meigs JV (1954). Pelvic tumors other than fibromas of the ovary with ascites and hydrothorax. *Obstet Gynecol.* **3**: 471–86.