

# Acute toxicity effect of cypermethrin on common carp (*Cyprinus carpio*)

Alzbeta STARA, Eliska ZUSKOVA, Josef VELISEK

Research Institute of Fish Culture and Hydrobiology, Faculty of Fisheries and Protection of Waters, South Bohemian Research Center of Aquaculture and Biodiversity of Hydrocenoses, University of South Bohemia in Ceske Budejovice, Czech Republic

Correspondence to: Dipl.-Ing. Alzbeta Stara, PhD.  
University of South Bohemia in Ceske Budejovice, Faculty of Fisheries and Protection of Waters, South Bohemian Research Center of Aquaculture and Biodiversity of Hydrocenoses, Research Institute of Fish Culture and Hydrobiology  
Zatisi 728/II 389 25 Vodnany, Czech Republic.  
TEL: +420 383 384 622 ; E-MAIL: staraa01@frov.jcu.cz

Submitted: 2016-06-24 Accepted: 2016-10-30 Published online: 2016-12-18

Key words: pesticide; fish; haematology; oxidative stress; antioxidants biomarkers; histology

Neuroendocrinol Lett 2016;37(Suppl. 1):60–66 PMID: 28263532 NEL370916A08 © 2016 Neuroendocrinology Letters • www.nel.edu

## Abstract

**OBJECTIVES:** The present study aimed to assess the acute effect of cypermethrin on common carp (*Cyprinus carpio*). Evaluation of toxicity effects of cypermethrin on carp was performed on based assessment of hematological profile, antioxidant and oxidative biomarkers and histopathology.

**METHODS:** For testing of toxicity was used the commercial product Cyperkill 25 EC – CY, which contains 250 g.L<sup>-1</sup> of cypermethrin. Carp were exposed to two concentrations (1CY – 4.57 µg.L<sup>-1</sup> and 2CY – 45.7 µg.L<sup>-1</sup>) of CY and a control for 96 hours.

**RESULTS:** Significant reduction ( $p < 0.05$ ) in leukocyte count were in fish exposed to concentration 45.7 µg.L<sup>-1</sup> (2CY). The both exposure of CY lead to significant differences ( $p < 0.01$ ) in antioxidants biomarkers (superoxide dismutase, catalase, glutathione reductase, reduced glutathione and glutathione S-transferase) and in lipid peroxidation in carp tissues. Many of these changes were observed in liver, gills, muscle, intestine, brain and kidney. Additionally, exposure to CY caused many histological changes in gills, liver and caudal kidney.

**CONCLUSION:** Exposure to CY caused hematological, biochemical and histopathological changes in carp. This study provides and complements other important results for evaluating the toxicity effect of pyrethroids on fish.

## Abbreviations:

96hLC50	- 96 hours median lethal concentration	Leuko	- leukocyte count
CAT	- catalase	LPO	- lipid peroxidation
CY	- Cyperkill 25 EC	MCH	- mean erythrocyte hemoglobin
EC	- emulsifiable concentrate	MCHC	- mean corpuscular hemoglobin concentration
Er	- erythrocyte count	MCV	- mean erythrocyte volume
GC/ECD	- gas chromatograph equipped with an electron capture detector	OECD	- the Organisation for Economic Co-operation and Development
GPx	- glutathione peroxidase	oed	- interstitial oedema
GR	- glutathione reductase	PCV	- hematocrit
GSH	- reduced glutathione	ROS	- reactive oxygen species
GSSG	- oxidized glutathione	SD	- standard deviation
GST	- glutathione S-transferase	SOD	- superoxide dismutase
Hb	- hemoglobin concentration	TBARS	- thiobarbituric acid reactive substances
		US EPA	- United States Environmental Protection Agency

## INTRODUCTION

Pyrethroids are synthetic chemicals that are in structure very similar to natural pyrethrins that were originally found in the flowers of *Chrysanthemum cinerariaefolium* (Todd *et al.* 2003). The first pyrethroids were developed in 1949 in America. They are around twenty times more effective at killing insects than DDT without the serious environmental or health impacts. In addition of the past decade, pyrethroids has increased the use chiefly at the expense of declining use of organophosphate pesticides in agriculture, which are more acutely toxic to birds and mammals than the pyrethroids (US EPA 2016).

Cypermethrin is a highly active insecticide against a wide range of pests in agriculture and public health which was first marketed in 1977 (WHO 1989). In nowadays, cypermethrin is still widely used insecticide, primarily because of its slow resistance in pest and slightly to moderately toxicity to mammals and practically nontoxicity to birds (Aggarwal *et al.* 2015). On the other hand, it is considered to be moderately to very highly toxic for aquatic organisms, for example acute toxicity 96hLC50 for *Diptomus forbesi* is 0.03  $\mu\text{g}\cdot\text{L}^{-1}$  (Saha & Kaviraj 2008), for carp larvae is estimated from 0.53 to 1.31  $\mu\text{g}\cdot\text{L}^{-1}$  (Aydin *et al.* 2005), for carp juvenile is 2.91  $\mu\text{g}\cdot\text{L}^{-1}$  (Dobsikova *et al.* 2006), for rainbow trout (*Oncorhynchus mykiss*) is 3.14  $\mu\text{g}\cdot\text{L}^{-1}$  (Velisek *et al.* 2006) and for Indian major carp (*Catla catla* L.) is 4  $\mu\text{g}\cdot\text{L}^{-1}$  (Tandon *et al.* 2005). Cypermethrin is very rapidly degraded with half-life of about 5 days in river water (Kidd & James 1991) and through it is very frequently detected in surface waters, the values that have been commonly detected ranged from 0.1 to 194  $\mu\text{g}\cdot\text{L}^{-1}$  (WHO 1989; Marino & Ronco 2005).

This study was aimed to broaden knowledge about the effect of cypermethrin on fish respectively carp by using the hemetological, histological examination and determination of the activity of antioxidant biomarkers and oxidative damage after acute exposure. This parameters are frequently used for detecting or diagnosing toxic effects of xenobiotics in fish because they are sensitive index to change due to pollutants toxicity and constitute important tools in the evaluation of toxicological studies (Ojutiku *et al.* 2013; Stara *et al.* 2015).

## MATERIALS AND METHODS

### Experimental animals

The common carp (*Cyprinus carpio*) were obtained from a local commercial hatchery (Vodnany, Czech Republic). The fish were one and one half year old with a mean total length 22.77 $\pm$ 2.12 cm and weight 175.56 $\pm$ 41.79 g.

### Chemical

Commercial pesticides product Cyperkill 25 EC (CY) has been used, it contained 250  $\mu\text{g}\cdot\text{L}^{-1}$  of active substance

cypermethrin ([3-[(6-chloropyridin-3-yl)methyl]-1,3-thiazolidin-2-ylidene]cyanamide).

### Experimental protocol

Seventy two fish were randomly divided into six tanks (volume 200 L, aeration) in each 12 fish were for 10 days of acclimatization before start of the experiment. After acclimatization period fish were exposed in duplicate to acute exposure of cypermethrin in concentrations 1CY = 4.57  $\mu\text{g}\cdot\text{L}^{-1}$  (10% 96hLC50) and 2CY = 45.7  $\mu\text{g}\cdot\text{L}^{-1}$  (96hLC50). Simultaneously the control fish were observed in the tanks with CY-free water for a period 96 hours. The trial was performed semi-statically with the bath and solution exchange every 12 h. The tested CY concentrations were maintained at above 80% of the nominal concentration throughout the experimental exposure. The CY concentrations in water were analysed using gas chromatography with electron capture detection (GC/ECD) (Mekebri *et al.* 2008). Fish were not fed during the experiment. Behavioural changes and the number of dead fish was recorded in each concentration each day during the tests. Water had dissolved oxygen concentration of 97.5 $\pm$ 2.6%, temperature 19.7 $\pm$ 0.5  $^{\circ}\text{C}$ , pH 7.7 $\pm$ 0.5 and light cycle was 12L:12D. Basic physical and chemical parameters of diluting water were: acid neutralisation capacity – ANC<sub>4.5</sub> 1.10 mmol.L<sup>-1</sup>, sum of Ca and Mg 8.91 mg.L<sup>-1</sup>, total ammonia 0.03 mg.L<sup>-1</sup>, NO<sub>3</sub><sup>-</sup> 5.92 mg.L<sup>-1</sup>, NO<sub>2</sub><sup>-</sup> 0.02 mg.L<sup>-1</sup>, PO<sub>4</sub><sup>3-</sup> 0.02 mg.L<sup>-1</sup> and COD<sub>Mn</sub> 1.1 mg.L<sup>-1</sup>.

After 96h acute exposure 3 fish were randomly removed from each tank (6 fish for a group) for hematological assessment and then they were killed for tissues sampling (liver, gills, muscle, intestine, brain and kidney) for oxidative stress and antioxidants analysis and tissues (liver, gills, and kidney) for the histological determination.

### Hematological examination

Blood was sampled from the *vena caudalis* using heparinised syringe (Heparin inj., Leciva, Czech Republic) at heparin sodium salt concentration of 0.01 mL per 1 mL blood. The measured indices for evaluation of the hematological profile included erythrocyte count (Er), hemoglobin concentration (Hb), hematocrit (PCV), mean erythrocyte volume (MCV), mean erythrocyte hemoglobin (MCH), mean colour concentration (MCHC) and leukocyte count (Leuko). The procedures were based on unified methods for haematological examination of fish by Svobodova *et al.* (1991).

### Antioxidants biomarkers and oxidative stress parameter

Fish were killed by stunning and exsanguination after blood sampling and consequently tissues were quickly removed and placed on ice and immediately frozen and stored at -80  $^{\circ}\text{C}$  for analysis. Subsequently individual frozen samples were weighed and homogenized in buffer (100 mg of tissue in 1 mL of buffer) for analysis. Samples prepared for determination anti-

oxidants biomarkers were centrifuged and measured spectrophotometrically. Superoxide dismutase (SOD; EC 1.15.1.1) activity was determined by the method Marklund & Marklund (1974), catalase (CAT; EC 1.11.1.6) activity was measured by the method Beers & Sizer (1952), glutathione reductase (GR; EC 1.6.4.2) activity was performed by the method of Carlberg & Mannervik (1975), reduced glutathione (GSH) level was determined by the method Ellman (1959), and glutathione S-transferase (GST; EC 2.5.1.18) activity was carried out according Habig *et al.* (1974). The level of lipid peroxidation was determined without centrifugation of sample homogenate described by Lushchak *et al.* (2005) used by method thiobarbituric acid reactive substances (TBARS).

### Histopathology

Immediately after the killing of fish were also removed samples of gills, liver and kidney and were placed into the 10% buffered formalin for histological processing. After 24 hours of fixation, the tissues were dehydrated in graded ethanol and embedded in paraffin. Cut sections of 5 µm were stained with hematoxylin and eosin, examined by light microscopy, and photographed using a digital camera.

### Ethical statement

The trial were performed in compliance with institutional guidelines and national legislation by Act. No. 246/1992 Coll., on the Protection of Animals Cruelly, as amended.

### Statistical analysis

Data was expressed as mean ± SD. STATISTICA version 12.0 for Windows (StatSoft, Inc.) was used to perform the statistical analysis. Kolmogorov-Smirnov and Bartlett's tests were applied to assess data for normal distribution and homoscedasticity of variance respectively. One-way ANOVA was used for data with normal distribution. In case of non-normal distribution, a non-parametric Kruskal-Wallis test was performed. The significance levels for tests were  $p < 0.05$  and  $p < 0.01$ .

## RESULTS

### Fish behaviour

Fish in control trial exhibited normal behaviour and none died during the test. Cypermethrin caused almost 13% mortality of carp in concentration 1CY which corresponds to 10% 96hLC50 and 46% carp died in concentration 2CY (96hLC50) during the 96 hours. Additionally fish at the highest concentration of cypermethrin showed a marked change in behaviour in comparison to other fish. Hyperactivity and hyperventilation were observed in fish which alternated with the attenuation phase, and it was accompanied by jerky movements of the body, erratic swimming and fish laying on the side. This led to exhaustion of the organ-

ism and the subsequent death of several fish after exposure to a toxic dose.

### Hematological examination

The results of the hematological parameters are presented in the Table 1. The exposure to cypermethrin led to significant decrease ( $p < 0.05$ ) in leukocyte count in fish exposed to concentration 2CY.

### Antioxidants biomarkers and oxidative stress parameter

The effect of acute exposure to cypermethrin on antioxidant biomarkers and oxidative stress in carp are presented in Table 2. Significantly lower ( $p < 0.01$ ) SOD activity was observed in fish exposed to both tested concentration to CY in liver, gills, intestine and brain. The GR activity was significantly lower ( $p < 0.01$ ) in fish in both experimental concentrations to CY in gills and intestine, GR increases were observed in muscle in fish for group 2CY. Exposure to cypermethrin had statistically significant effect ( $p < 0.01$ ) on CAT activity in liver in fish from group 2CY and brain in both tested concentrations to CY which reduced the CAT activity and in muscle exposure to 2CY lead to increases in this activity compared with control fish. The GST activity was significantly lower ( $p < 0.01$ ) in liver in fish exposed in both CY tested concentrations and kidney in the highest tested concentration 2CY. The higher GR activity was detected in gills in fish from the group 2CY and in muscle in both tested concentration CY. The GSH contents increased in gills and muscle in fish both treated groups to CY. The TBARS level was significantly ( $p < 0.01$ ) higher in gills and lower in brain only in 2CY group compared to the control group.

### Histopathology

Gills of exposed fish were characterized by hyperplasia, lamellar fusion, swelling and lifting of epithelial cells. The most pronounced pathologies were noticed in the group 2CY (Figure 1).

**Tab. 1.** Hematological parameters in carp (*Cyprinus carpio*) after acute exposure 96 h to Cyperkill 25 EC (CY).

Indices	Control (0 µg.L <sup>-1</sup> )	1CY (4.57 µg.L <sup>-1</sup> )	2CY (45.7 µg.L <sup>-1</sup> )
PCV (L.L <sup>-1</sup> )	0.26±0.03 <sup>a</sup>	0.24±0.03 <sup>a</sup>	0.29±0.05 <sup>a</sup>
Hb (g.L <sup>-1</sup> )	61.71±10.26 <sup>a</sup>	59.03±8.24 <sup>a</sup>	71.26±15.24 <sup>a</sup>
Er (T.L <sup>-1</sup> )	1.31±0.27 <sup>a</sup>	1.16±0.28 <sup>a</sup>	1.25±0.34 <sup>a</sup>
MCV (fl)	203.74±25.93 <sup>a</sup>	217.23±69.38 <sup>a</sup>	245±63.67 <sup>a</sup>
MCH (pg)	47.50±5.02 <sup>a</sup>	52.63±10.83 <sup>a</sup>	61.08±22.00 <sup>a</sup>
MCHC (L.L <sup>-1</sup> )	0.23±0.01 <sup>a</sup>	0.25±0.05 <sup>a</sup>	0.25±0.05 <sup>a</sup>
Leuko (G.L <sup>-1</sup> )	75.33±20.67 <sup>a</sup>	79.67±27.01 <sup>a</sup>	42.50±16.81 <sup>b</sup>

Data are means ± standard deviation. Different letters in columns show significant difference ( $p < 0.05$ ).

**Tab. 2.** Activities of antioxidant enzymes and lipid peroxidation in carp (*Cyprinus carpio*) after acute exposure 96 h to Cyperkill 25 EC (CY).

Indices	Group	Tissues					
		Liver	Gills	Muscle	Intestine	Brain	Kidney
SOD (nmol NBT.min <sup>-1</sup> .mg <sup>-1</sup> protein)	Control	0.205±0.05 <sup>a</sup>	0.250±0.07 <sup>a</sup>	0.037±0.02 <sup>a</sup>	0.390±0.07 <sup>a</sup>	0.696±0.09 <sup>a</sup>	0.068±0.03 <sup>a</sup>
	1CY	0.156±0.07 <sup>ab</sup>	0.214±0.02 <sup>ab</sup>	0.138±0.11 <sup>a</sup>	0.280±0.31 <sup>b</sup>	0.356±0.09 <sup>b</sup>	0.109±0.06 <sup>a</sup>
	2CY	0.095±0.02 <sup>b</sup>	0.119±0.04 <sup>b</sup>	0.225±0.31 <sup>a</sup>	0.212±0.04 <sup>b</sup>	0.119±0.02 <sup>c</sup>	0.128±0.08 <sup>a</sup>
GR (nmol NADPH.min <sup>-1</sup> .mg <sup>-1</sup> protein)	Control	0.177±0.06 <sup>a</sup>	0.898±0.23 <sup>a</sup>	0.035±0.03 <sup>a</sup>	0.304±0.10 <sup>a</sup>	0.085±0.03 <sup>a</sup>	0.185±0.10 <sup>a</sup>
	1CY	0.166±0.03 <sup>a</sup>	0.471±0.11 <sup>b</sup>	0.039±0.03 <sup>a</sup>	0.111±0.05 <sup>b</sup>	0.063±0.05 <sup>a</sup>	0.318±0.13 <sup>a</sup>
	2CY	0.142±0.07 <sup>a</sup>	0.234±0.08 <sup>b</sup>	0.118±0.04 <sup>b</sup>	0.052±0.03 <sup>b</sup>	0.130±0.07 <sup>a</sup>	0.389±0.20 <sup>a</sup>
CAT (μmol H <sub>2</sub> O <sub>2</sub> .min <sup>-1</sup> .mg <sup>-1</sup> protein)	Control	0.520±0.14 <sup>a</sup>	0.077±0.04 <sup>a</sup>	0.134±0.05 <sup>a</sup>	0.119±0.06 <sup>a</sup>	0.030±0.00 <sup>a</sup>	0.521±0.14 <sup>a</sup>
	1CY	0.502±0.15 <sup>a</sup>	0.071±0.02 <sup>a</sup>	0.056±0.03 <sup>b</sup>	0.129±0.07 <sup>a</sup>	0.058±0.01 <sup>b</sup>	0.467±0.07 <sup>a</sup>
	2CY	0.937±0.15 <sup>b</sup>	0.109±0.01 <sup>a</sup>	0.016±0.00 <sup>b</sup>	0.212±0.03 <sup>a</sup>	0.066±0.02 <sup>b</sup>	0.417±0.06 <sup>a</sup>
GST (nmol <sup>-1</sup> .min <sup>-1</sup> .mg <sup>-1</sup> protein)	Control	1.106±0.14 <sup>a</sup>	0.538±0.07 <sup>a</sup>	0.046±0.01 <sup>a</sup>	0.350±0.05 <sup>a</sup>	0.434±0.05 <sup>a</sup>	0.873±0.11 <sup>a</sup>
	1CY	0.939±0.09 <sup>ab</sup>	0.531±0.03 <sup>a</sup>	0.137±0.04 <sup>b</sup>	0.371±0.09 <sup>a</sup>	0.427±0.05 <sup>a</sup>	0.872±0.25 <sup>a</sup>
	2CY	0.876±0.09 <sup>b</sup>	0.675±0.04 <sup>b</sup>	0.144±0.04 <sup>b</sup>	0.409±0.11 <sup>a</sup>	0.467±0.05 <sup>a</sup>	0.567±0.09 <sup>b</sup>
GSH (nmol GSH.mg <sup>-1</sup> protein)	Control	49.374±9.56 <sup>a</sup>	15.433±2.40 <sup>a</sup>	5.778±1.21 <sup>a</sup>	17.774±4.43 <sup>a</sup>	18.217±1.59 <sup>a</sup>	41.329±13.17 <sup>a</sup>
	1CY	48.791±7.59 <sup>a</sup>	19.856±2.06 <sup>ab</sup>	9.040±1.67 <sup>b</sup>	17.411±4.53 <sup>a</sup>	14.922±4.77 <sup>a</sup>	30.464±19.27 <sup>a</sup>
	2CY	43.308±9.68 <sup>a</sup>	20.741±4.51 <sup>b</sup>	10.322±2.62 <sup>b</sup>	14.791±3.13 <sup>a</sup>	14.791±3.13 <sup>a</sup>	20.501±9.21 <sup>a</sup>
TBARS (nmol.mg <sup>-1</sup> protein)	Control	0.497±0.03 <sup>a</sup>	0.193±0.06 <sup>a</sup>	0.310±0.08 <sup>a</sup>	0.307±0.09 <sup>a</sup>	0.331±0.05 <sup>a</sup>	0.474±0.10 <sup>a</sup>
	1CY	0.491±0.03 <sup>a</sup>	0.252±0.02 <sup>ab</sup>	0.336±0.04 <sup>a</sup>	0.366±0.10 <sup>a</sup>	0.323±3.04 <sup>a</sup>	0.464±0.14 <sup>a</sup>
	2CY	0.447±0.04 <sup>a</sup>	0.318±0.07 <sup>b</sup>	0.397±0.12 <sup>a</sup>	0.387±0.24 <sup>a</sup>	0.243±0.03 <sup>b</sup>	0.440±0.04 <sup>a</sup>

Data are means ± standard deviation. Different letters in columns show significant difference ( $p < 0.01$ ).

Structure of liver revealed the presence of steatosis in all groups. Furthermore, extensive hyperaemia together with perivascular oedema were observed in group 2CY (Figure 2). The histological changes in caudal kidney of exposed groups were represented by focal extensive hyperaemia as well as by vacuolisation of tubular epithelial cells. The intensity of described pathologies grows with increasing cypermethrin concentration. Moreover, focal disintegration of the convoluted tubules was found in group 2CY (Figure 3).

## DISCUSSION

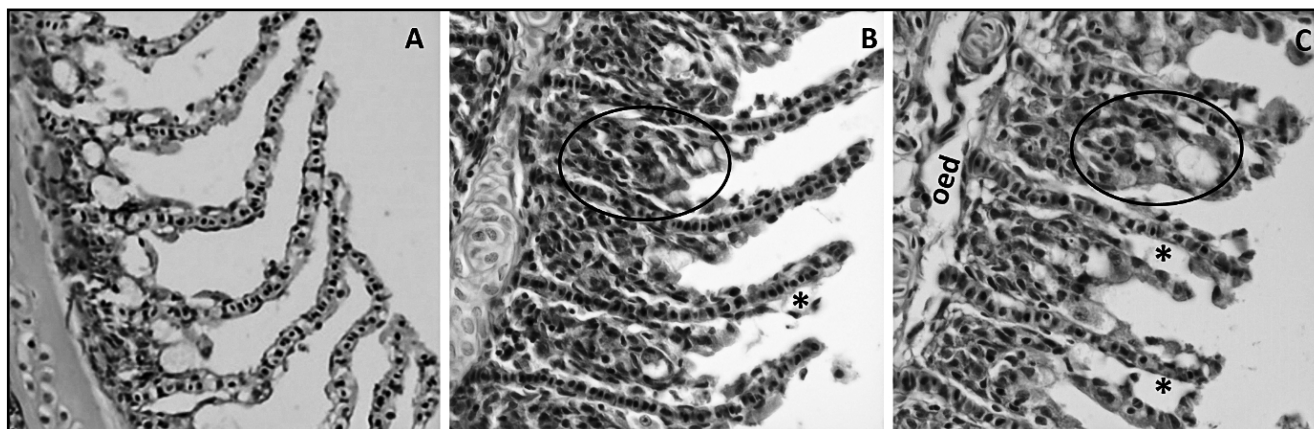
Our results show acute effect of cypermethrin on physiology of carp. We used insecticide product Cyperkill 25 EC for experiment which is used for killing and controlling a wide spectrum of voracious pests by contact with it or such as ingestion poison.

Behavioural changes are the first visible changes during acute poisoning. We observed neural and respiratory changes in carp behaviour which are typical for fish exposed to high concentrations of pyrethroids and they have been observed in other studies (Borges *et al.* 2007; Velisek *et al.* 2011; Stara *et al.* 2013, 2015).

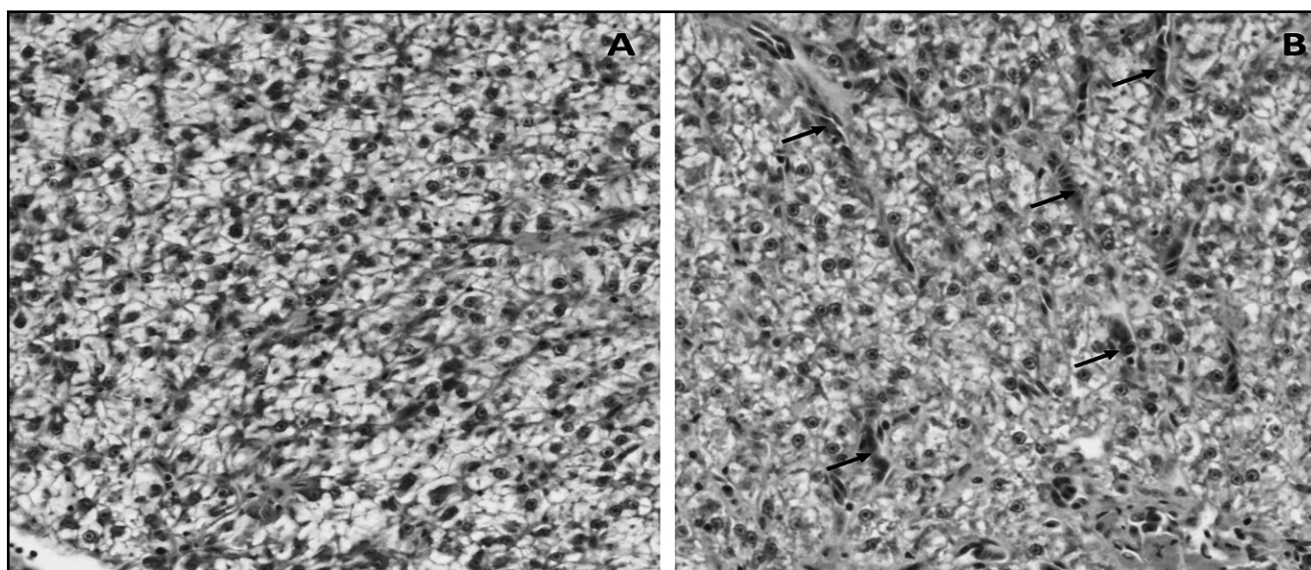
The results of the hematological parameters can be useful when evaluating toxic effect in fish. The exposure to cypermethrin lead to significant decrease only

in leukocyte count in carp exposed to high concentration 2CY. Exposure to pyrethroids has influenced hematological responses in several studies. Differences in hematological indices after acute exposure to cypermethrin observed Dobsikova *et al.* (2006) in Er, MCV and MCH in carp and Ullah *et al.* (2015) in Er and Leuko in mahseer (*Tor putitora*). Borges *et al.* (2007) had increased MCHC and Hb in jundiá (*Rhamdia quelen*) after sub-lethal toxicity of cypermethrin. On the other hand, Velisek *et al.* (2006) reported no effect on the haematological indices after acute exposure of cypermethrin to rainbow trout.

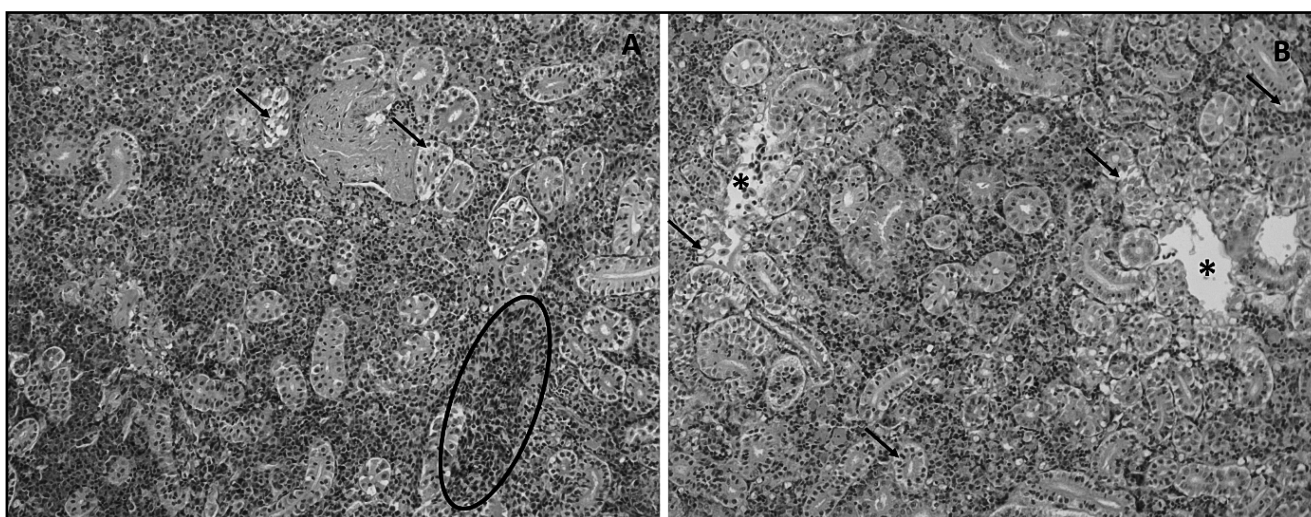
Reactive oxygen species (ROS) are naturally contained in the cells and antioxidant biomarkers maintaining balance in the ROS production in cells and thus protects organism against oxidative damage. On the creation and production of these biomarkers may have effect mainly changes in the environment in which the organism is located (e.g. temperature, pH, food, xenobiotics etc.) and can lead to oxidative damage (Rahman 2007; Stancova *et al.* 2015). Overproduction of ROS were in gills in both tested concentration to CY and low production in brain after acute exposure to 2CY. Changes in antioxidant biomarkers SOD, CAT, GR, GST and GSH in chosen tissues were observed after exposure to both tested concentration to cypermethrin. Acute exposure to cypermethrin lead to overproduc-



**Fig. 1.** Gills of carp (*Cyprinus carpio*) after acute exposure 96 h to Cyperkill 25 EC (CY). Haematoxylin and eosin, x 400. A – control group; B – group 1CY ( $4.57 \mu\text{g.L}^{-1}$ ); C – group 2CY ( $45.7 \mu\text{g.L}^{-1}$ ); The asterisks indicate lifting of epithelial cells; The ovals mark hyperplasia of basal epithelium resulted up to lamellar fusion; oed – interstitial oedema.



**Fig. 2.** Liver of carp (*Cyprinus carpio*) after acute exposure 96 h to Cyperkill 25 EC (CY). Haematoxylin and eosin, 400x. A – control group; B – group 2CY ( $45.7 \mu\text{g.L}^{-1}$ ); The arrows mark extensive hyperaemic places.



**Fig. 3.** Kidney of carp (*Cyprinus carpio*) after acute exposure 96 h to Cyperkill 25 EC (CY). Haematoxylin and eosin, 200x. A – group 1CY ( $4.57 \mu\text{g.L}^{-1}$ ); B – group 2CY ( $45.7 \mu\text{g.L}^{-1}$ ); See hyperaemic place in oval. The arrows mark vacuolisation of tubular epithelial cells; the asterisks indicate disintegrated tissue with destroyed tubular epithelium.

tion of ROS and changes in CAT and GR activities in mahseer tissues (Ullah *et al.* 2014). Early life stages of carp which were exposed to concentration  $7.2 \mu\text{g}\cdot\text{L}^{-1}$  of cypermethrin had lower GPx, GR and GST activities and lipid peroxidation was not demonstrated after 35 days (Richterova *et al.* 2015). Acute exposure of carp to zeta-cypermethrin lead to changes in SOD, CAT and GR activities, but oxidative damage have not been observed (Stara *et al.* 2013).

The gills participate in many important functions in fish such as respiration, osmoregulation and excretion. Their external location renders them the most vulnerable target organ of the contaminants (Robert 1989; Poleksic and Mitrovic-Tutundzic 1994). Gills of carp exposed to CY were characterized by hyperplasia, lamellar fusion, swelling and lifting of epithelial cells. Such histopathological changes could be therefore considered as non-specific occurring after fish exposures to metals (Martinez *et al.* 2004), pesticides (Stara *et al.* 2015; Stoyanova *et al.* 2015; Murussi *et al.* 2016) and other chemistry different contaminants.

Fish liver revealed steatosis in all groups and that changes could be considered as normal finding because fish hepatocytes tend to be more vacuolated and correspond to a relatively higher glycogen and/or lipid content. Such vacuolization, is often and especially apparent in the livers of captive fishes, where artificial feeding and housing conditions cause imbalances in energy intake and expenditure (Wolf & Wolfe 2005). Similar circulatory and degenerative alterations of liver such as vein congestion and glycol/fatty infiltration of hepatocytes were reported by Ayoola & Ajani (2008), who evaluated cypermethrin toxicity on juvenile African catfish (*Clarias gariepinus*).

Caudal kidney are one of the first organs to be affected by contaminants in the water, because they play important role in the excretion of harmful substances. Despite the findings of Velisek *et al.* (2009), who has not found any changes in the parenchyma of kidney after acute exposure to bifenthrin. The present study has proved occurrence of several histological alterations in the kidney which are results from cypermethrin toxicity such focal extensive hyperaemia as well as vacuolisation of tubular epithelial cells.

## CONCLUSION

This study provides and add important information about toxic effect of cypermethrin on carp. The chosen parameters (behaviour, biochemical, histological) seem to be appropriately selected for evaluating the toxic effects of pesticide to damage of fish. In conclusion, the cypermethrin is toxic for fish in relevantly low concentrations and the results are suitable for evaluating ecotoxicological impact on non-target organisms, respectively fish.

## ACKNOWLEDGMENTS

The study was financially supported by the Ministry of Education, Youth and Sports of the Czech Republic – projects „CENAKVA“ (No. CZ.1.05/2.1.00/01.0024), “CENAKVA II“ (No. LO1205 under the NPU I program).

## REFERENCES

- Aggarwal P, Jamshed N, Ekka M, Imran A (2015). Suicidal poisoning with cypermethrin: A clinical dilemma in the emergency department. *J Emerg Trauma Shock*. **8**: 123–125.
- Aydin R, Koprucu K, Dorucu M, Koprucu SS, Pala M (2005). Acute toxicity of synthetic pyrethroid cypermethrin on the common carp (*Cyprinus carpio* L.) embryos and larvae. *Aquaculture Intern*. **13**: 451–458.
- Ayoola SO, Ajani EK (2008). Histopathological effects of cypermethrin on juvenile African catfish (*Clarias gariepinus*). *World J Biol Res*. **1**: 1–14.
- Beers RF, Sizer IW (1952). A spectrophotometric method for measuring the breakdown of hydrogen peroxide by catalase. *J Biol Chem*. **195**: 133–140.
- Borges A, Scotti LV, Siqueira DR, Zanini R, do Amaral F, Jurinitz DF, Wassermann GF (2007). Changes in hematological and serum biochemical values in jundia *Rhamdia quelen* due to sub-lethal toxicity of cypermethrin. *Chemosphere* **69**: 920–926.
- Carlberg I, Mannervik B (1975). Purification and characterization of flavoenzyme glutathione reductase from rat liver. *J Biol Chem*. **250**: 5475–5480.
- Dobsikova R, Velisek J, Wlasow T, Gomulka P, Svobodova Z, Novotny L (2006). Effects of cypermethrin on some haematological, biochemical and histopathological parameters of common carp (*Cyprinus carpio* L.). *Neuroendocrinol Lett*. **27**: 91–95.
- Ellman GL (1959). Tissue sulfhydryl groups. *Arch Biochem Biophys*. **82**: 70–77.
- Kidd H, James DR (1991). *The Agrochemicals Handbook*. Third Edition. Royal Society of Chemistry Information Services, Cambridge, UK, pp 6–10.
- Habig WH, Pabst MJ, Jakoby WB (1974). Glutathione S-transferases – first enzymatic step in mercapturic acid formation. *J Biol Chem*. **249**: 7130–7139.
- Lushchak VI, Bagnyukova TV, Husak VV, Luzhna LI, Lushchak OV, Storey KB (2005). Hyperoxia results in transient oxidative stress and an adaptive response by antioxidant enzymes in goldfish tissues. *Int J Biochem Cell Biol*. **37**: 1670–1680.
- Marino D, Ronco A (2005). Cypermethrin and chlorpyrifos concentration levels in surface water bodies of the Pampa Ondulada, Argentina. *Bull Environ Contam Toxicol*. **75**: 820–826.
- Marklund S, Marklund G (1974). Involvement of superoxide anion radical in autoxidation of pyrogallol and a convenient assay for superoxide dismutase. *Eur J Biochem*. **47**: 469–474.
- Martinez CBR, Nagae MY, Zaia CTBV, Zaia DAM (2004). Morphological and physiological acute effects of lead in the neotropical fish *Prochilodus lineatus*. *Braz J Biol*. **64**: 797–807.
- Mekebri A, Crane DB, Blondina GJ, Oros DR, Rocca JL (2008). Extraction and analysis methods for the determination of pyrethroid insecticides in surface water, sediments and biological tissues at environmentally relevant concentrations. *Bull Environ Contam Toxicol*. **80**: 455–460.
- Murussi CR, Costa MD, Leitemperger JW, Flores-Lopes F, Menezes CC, Loebens L, de Avila LA, Rizzetti TM, Adaime MB, Zanella R *et al.* (2016). Acute exposure to the biopesticide azadirachtin affects parameters in the gills of common carp (*Cyprinus carpio*). *Comp Biochem Physiol C*. **180**: 49–55.
- Ojutiku RO, Asuwaju FP, Ayanda O, Obande RA, Agbelege OO (2013). Effect of acute toxicity of cypermethrin on some biochemical parameters of juveniles of *Claria Gariepinus*. (Burchell, 1822). *Int J Eng Sci Invent*. **2**: 1–7.

- 18 Poleksic V, Mitrovic-Tutundzic V (1994). Fish gills as a monitor of sublethal and chronic effects of pollution. In: Müller, R. & R. Lloyd (Eds.) Sublethal and Chronic effects of pollutants on freshwater fish. Oxford, Fishing News Books, pp. 339–352.
- 19 Rahman K (2007). Studies on free radicals, antioxidants, and co-factors. *Clin Interv Aging*. **2**: 219–236.
- 20 Richterova Z, Machova J, Stara A, Tumova J, Velisek J, Sevcikova M, Svobodova Z (2015). Effects of a cypermethrin-based pesticide on early life stages of common carp (*Cyprinus carpio* L.). *Vet Med* **60**: 423–431.
- 21 Robert RJ (1989). *Fish Pathology*. Bailliere Tindall, London.
- 22 Saha S, Kaviraj CA (2008). Acute toxicity of synthetic pyrethroid cypermethrin to some freshwater organisms. *Bull Environ Contam Toxicol*. **80**: 49–52.
- 23 Stancova V, Plhalova L, Tichy F, Doubkova V, Marsalek P, Hostovsky M, Svobodova Z (2015). Oxidative stress indices and histopathological effects of the nonsteroidal antiinflammatory drug naproxen in adult zebrafish (*Danio rerio*). *Neuroendocrinol Lett*. **36**: 73–78.
- 24 Stara A, Steinbach C, Wlasow T, Gomulka P, Ziemok E, Machova J, Velisek J (2013). Effect of zeta-cypermethrin on common carp (*Cyprinus carpio* L.). *Neuroendocrinol Lett*. **34**: 37–42.
- 25 Stara A, Zuskova E, Machova J, Priborsky J, Velisek J (2015). Effect of acute exposure to deltamethrin and recovery time on common carp (*Cyprinus carpio* L.). *Neuroendocrinol Lett*. **36**: 133–140.
- 26 Stoyanova S, Yancheva VS, Velcheva I, Uchikova E, Georgieva E (2015). Histological Alterations in Common Carp (*Cyprinus carpio* Linnaeus, 1758) Gills as Potential Biomarkers for Fungicide Contamination. *Braz Arch Biol Technol*. **58**: 757–764.
- 27 Svobodova Z, Pravda D, Palackova J (1991). Unified methods of haematological examination of fish. Research Institute of Fish Culture and Hydrobiology, Vodnany, Methods No. 20, 31 pp.
- 28 Tandon SS, Srivastava PP, Mukherjee SC, Saharan N (2005). Acute toxicity of synthetic pyrethroids to Indian major carp, *Catla catla* L. *Bull Environ Contam Toxicol*. **74**: 610–613.
- 29 Todd GD, Wohlers D, Citra M (2003). Toxicology profile for pyrethrins and pyrethroids. Agency for Toxic Substances and Disease Registry, Department of Health and Human Services. Atlanta, GA, U.S., 328 pp.
- 30 Ullah R, Zuberi A, Ullah S, Ullah I, Ullah Dawar F (2014). Toxicity to hematology and morphology of liver, brain and gills during acute exposure of mahseer (*Tor putitora*) to cypermethrin. *J Toxicol Sci*. **39**: 829–836.
- 31 Ullah R, Zuberi A, Naeem M, Ullah S (2015). Toxicity to hematology and morphology of liver, brain and gills during acute exposure of mahseer (*Tor putitora*) to cypermethrin. *Int J Agric Biol*. **17**: 199–204.
- 32 US EPA - United States Environmental Protection Agency (2016). Pesticides - Pesticide Registration Manual Helps Applicants. Available from: <https://www.epa.gov/pesticides>, (visited online 2/5/2016).
- 33 Velisek J, Wlasow T, Gomulka P, Svobodova Z, Dobsikova R, Novotny L, Dudzik M (2006). Effects of cypermethrin on rainbow trout (*Oncorhynchus mykiss*). *Vet Med* **51**: 469–476.
- 34 Velisek J, Svobodova Z, Piackova V (2009). Effects of acute exposure to bifenthrin on some haematological, biochemical and histopathological parameters of rainbow trout (*Oncorhynchus mykiss*). *Vet Med*. **54**: 131–137.
- 35 Velisek J, Stara A, Svobodova Z (2011). The effects of pyrethroid and triazine pesticides on fish physiology. In: Stoytcheva, M., (Ed.). Pesticides in the Modern World - Pests Control and Pesticides Exposure and Toxicity Assessment. InTech Open Access Publisher, pp. 377–402.
- 36 WHO - World Health Organisation (1989). Cypermethrin - Health and Safety Guide. Geneva No. 22, 107 pp.
- 37 Wolf JC, Wolfe MJ (2005). A brief overview of nonneoplastic hepatic toxicity in fish. *Toxicol Pathol*. **33**: 75–85.